

Histopathological Study of Ovarian Cystic Lesions at a Tertiary Care Hospital in India

Maitry D Charel¹, Smita A Shah², Hansa M. Goswami³

¹Post-graduate Resident, ²Associate Professor, ³Professor & Head, Department of Pathology, B. J. Medical College and Civil Hospital, Asarwa, Ahmedabad, Gujarat, India

Abstract

Introduction: Ovarian cysts are commonly encountered lesions. They are amongst the most frequent cause of hospitalization and surgery in gynecologic practice. One cannot confidently distinguish a benign lesion from a malignant one on the basis of clinical, radiological or gross characteristics alone so a histopathology examination is a must as it guides therapy. The study was undertaken to determine the morphologic spectrum of the cystic lesions of the ovary.

Method: This is a descriptive study which was carried out at B.J. Medical College, Ahmedabad for a period of two years from 1st July 2017 to 30th September 2019. A Total of 155 cases of ovarian cysts were received and processed in the Pathology Department. Hematoxylin and Eosin stained slides were examined.

Results: Out of 167 ovarian cystic lesions, 141 cases (85%) were unilateral and 26 cases (15%) were bilateral. There were 72 cases (43.1%) of benign cysts, 82 cases (49.1%) of benign tumors, 8 cases (4.7%) of malignant tumors and 5 cases (2.9%) of borderline epithelial tumors. The age of patients ranged from 12 years to 71 years with mean age of presentation of 43 years. Among the ovarian cystic lesions the incidence of mature cystic teratoma was the highest (26.3%). The most common non-neoplastic cyst was endometriotic cyst (40%), while the most common benign tumor was mature cystic teratoma (46.3%). The malignant tumor encountered in the study was serous cystadenocarcinoma. Two cases of borderline epithelial tumors (2.8%) were also observed in the study.

Conclusion: The most common cystic lesion that was encountered in the study was benign tumor followed by benign cyst. Of the benign tumors, mature cystic teratoma was the most frequently observed lesion. Among the non-neoplastic cysts, endometriotic cyst was the most frequently observed lesion. Keywords: borderline tumors, endometriosis cyst, mature cystic teratoma, Ovarian cyst, serous cystadenocarcinoma.

Introduction

Ovaries, a paired organ in female reproductive system is a vital organ of the woman body. Knowledge about ovaries is dated back to the time of Hemophilus,

but the term ovary was coined in 17th century. Even Shushruta has described ovarian neoplasm in his book "Shushruta and Ayurveda". Ovaries are a common site for non-neoplastic and neoplastic lesions. Distinguishing non-neoplastic lesion from a neoplastic lesion is a challenge clinically and is important in guiding therapy. These lesions behave in diverse ways and generally escape detection until they attain a large size or cause signs and symptoms. Typically, ovarian masses consist of functional and pathological lesions. Functional lesions are mainly cystic and are the most commonly encountered lesions of this retroperitoneal organ. Functional cyst consist of mainly follicular and corpus luteal cysts. Majority of the functional cysts

Corresponding author:

Dr. Maitry D Charel,

Resident Doctor, Department of Pathology,
B. J. Medical College and Civil Hospital, Asarwa,
Ahmedabad 380016, Gujarat, India
E-mail drmaity92charel@gmail.com
Phone number +918238941267

are simple cysts, while minority consists of complex cystic architecture. Studies have shown that 90% of these cysts are resolved spontaneously. These cysts are frequently seen in young female in their 2nd decade due to failure of ovulation. However, few cases could also be seen in perimenopausal and postmenopausal women. They show diverse morphological spectrum and can be categorized into benign cysts, benign, borderline and malignant tumors. Further subdivision of tumors can be done according to the WHO classification on the basis of tissue of origin into surface epithelial tumors, sex cord-stromal tumors, germ cell tumors, metastatic tumors and tumors from ovarian soft tissue or non-neoplastic process. While the benign lesions forming pelvic masses and mimicking ovarian tumors can be categorized into follicular cysts/ simple cysts, corpus luteal cysts, endometriotic cysts and hemorrhagic cysts. This distinction between non-neoplastic lesions and neoplastic lesion is necessary since proper treatment depends upon the histological abnormality. Hence this study was undertaken to determine the histopathological spectrum of these cystic lesions in our hospital.

Method

This descriptive study was done in the Department of Pathology, B.J.M.C, Ahmedabad over a period of two years from 1st July 2017 to 30th September 2019. Cases of ovarian cystic lesions which underwent oophorectomy or hysterectomy with bilateral/ unilateral salpingectomy were included in the study. Information regarding the age, clinical history, digital rectal examination, and clinical diagnosis was obtained. All specimens sent for histology were fixed in 10% formalin solution, processed with automated tissue processor, paraffin embedded, and sectioned at 3-5 microns using the microtome machine before staining with Hematoxylin and Eosin. The results obtained were analyzed. Special stains Reticulin and Periodic acid-Schiff stains were used where necessary.

Results

Most common presentation was abdominal pain followed by mass lesion on ultrasound and abnormal menstruation. Most of the patients were between the age of 10 to 70 years. Out of 167 cases, 141 cases (85%) were unilateral and 26 cases (15%) were bilateral. There were 72 cases (46.7%) of non-neoplastic cysts among which 63 cases presented as unilateral mass and nine cases presented as bilateral masses. Among the bilateral masses there were six cases of endometriotic cysts of

which one showed endometriosis even in the appendix. Size of the non-neoplastic cysts ranged from 3.2 cm to 11.8cm in diameter. The incidence of ovarian cysts and tumors is given in Table 1 below while Figure 1 shows the incidence of benign cysts comprising of various lesions

Table 1: Incidence of ovarian cysts and tumors

Types of cystic lesion	Number of cases	Number of cases (Percentage Distribution)
Endometriotic cyst	29	18%
Corpus luteal cyst	17	10%
Follicular cyst/ simple cyst	15	8.9 %
Hemorrhagic cyst	7	4.1 %
Infarcted ovary	4	2.3%
Mature cystic teratoma	44	26.3%
Serous cystadenoma	26	15.5 %
Mucinous cystadenoma	9	5.3%
Serous adenofibroma	3	1.7%
Serous cystadenocarcinoma	8	4.7%
Borderline papillary serous tumor	2	1.1%
Borderline mucinous tumor	3	1.7%

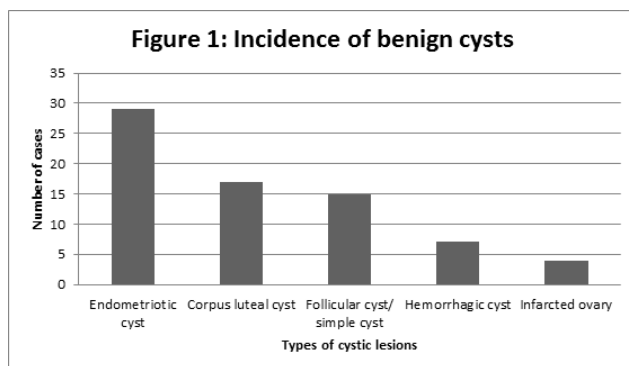


Figure 1: Incidence of benign cysts

There were 87 cases (52%) of benign tumors. The youngest patient in the study, a 12 year old had mature cystic teratoma and the oldest patient a 71year old had serous cyst adenocarcinoma .Size range for serous cystadenoma was from 3 to 12cm diameter, for mature cystic teratoma 4.5 to 11.5 cm diameter and for mucinous cystadenoma from 10 to 28cm diameter. The incidence of benign tumors is shown in Figure 2 below. There were five cases of bilateral mature cystic teratoma in the study.

There were eight cases (4.7%) of malignant tumors. The age range in the study for malignant tumors was 40 to 79 years. All the eight cases of malignant tumor in our study were serous cystadenocarcinoma (100%) of which five had bilateral involvement. Size of these tumors ranged from 6 to 19 cm diameter. The two borderline tumors in the study were mucinous tumor and papillary serous tumor of which the papillary serous tumor had bilateral involvement.

Discussion

Ovary is normally a partially cystic structure and that the risk of carcinoma developing in these cystic structures is negligible should help avoid many unnecessary unnecessary excisions¹. These lesions can be visualized sonographically in women of all ages. The presence of a single, unilocular, anechoic, thin-walled cystic mass measuring less than 3cm is considered within normal limits. Gynecologists for years have prescribed oral contraceptives for the resolution of functional ovarian cysts and to distinguish between them and pathological cysts of the ovary^{2,3}. However, follow-up is recommended if cysts exceed 3 cm. Some of these functional ovarian cysts resolve spontaneously.⁴ The non-neoplastic cysts commonly encountered are the follicular cysts, corpus luteum cysts, endometriotic cysts and hemorrhagic cysts. These cysts may mimic ovarian neoplasm clinically and grossly. They comprise a spectrum of morphologic changes whether physiological

or pathological.

In this study there were 167 cases of cystic lesions of which 72 cases (46.7%) were non-neoplastic cysts, 87 cases (52%) were benign tumors, eight cases (4.7%) were malignant tumors and five cases (2.9%) were borderline tumors. In comparison to a previous study done at the same center over a period of one and half year by Pudasaini S et al⁵ there were a total of 118 cases of ovarian cysts/ tumors with 89% benign cyst and tumors and 13% malignant tumors. In a study done by Zaman et al⁶, 498 cases were studied in one year. The authors encountered 68.87% of non-neoplastic lesions and 31.12% of neoplastic lesions. In our study, there were 43.7% of non-neoplastic lesions and 56.3% of neoplastic lesions.

Among the 72 cases of benign cysts (43.1%), there were 17 cases of corpus luteum cyst (10.1%), 29 cases of endometriosis (18%) and 7 cases of hemorrhagic cyst (4.1%) as compared to a previous study done by Pudasaini S.

S. et al⁵. The authors found 13.7% of haemorrhagic corpus luteal cysts and 5.9% cases of endometriotic cysts from a total of 118 cases. In a study done by Maliheh et al⁷, 2961 benign ovarian masses were examined. The authors found 57.1% cases of functional cyst followed by 5.9% cases of endometriotic cysts. In our study all cases of endometriosis were in the ovary with one case having endometriosis in the appendix too. Cohen et al⁸ have shown the ovary to be the commonest site for endometriosis..

There were 69 cases (51.1%) of benign tumors in the study of which 29 cases (42%) were benign epithelial tumors and 40 cases (58%) were benign germ cell tumors. The cases of benign epithelial tumors included serous cystadenoma (32%), mucinous adenoma (9%) and serous adenofibroma (1%). Benign Germ cell tumor encountered in the study was mature cystic teratoma (58%). Age range for patients with mature cystic teratoma was from 13 to 60 years. In our study incidence of mature cystic teratoma was higher in comparison to other studies. In the study done by Maliheh et al⁷, the most common benign tumor was serous cystadenoma (38%) followed by mature cystic teratoma (30%), mucinous cystadenoma (22%), adenofibroma (5%) and fibromathecoma (5%). In the study by Bhattacharya et al⁹, large majority of neoplastic tumors consisted of epithelial tumours (61.60%) and germ cell tumors (24.8%) followed by sex cord stromal tumors and malignant tumors. In the study done by Gupta et al¹⁰, surface epithelial tumours were the commonest (48.8%) followed by germ cell

tumours (23.9%), sex cord stromal tumours (8.3%) and metastatic tumours (2.0%). In a study done by Jha et al¹¹, surface epithelial tumors were most common (52.2%) followed by germ cell tumors (42.2%). In the study done by Mondal et al¹² the commonest benign tumor was serous cystadenoma (29.9%), followed by mature teratoma (15.9%) and mucinous cystadenoma (11.1%). In the study by Iqbal et al¹³, serous cystadenoma (38.5%) was the most common benign tumor followed by mature cystic teratoma (30.8%). In the study done by Yasmin et al¹⁴ the commonest benign tumor was also serous cystadenoma (24%) followed by mature cystic teratoma (18%).

In our study there were five cases (4.5%) of malignant tumor, all of which were (100%) were epithelial tumors. Malignant tumor observed in the study was serous cystadenocarcinoma. Though there were few cases of malignant tumor the results are similar to studies by Mondal et al¹² and Bhattacharya et al⁹ who also found surface epithelial tumors to be the commonest malignant tumor. There were two cases of borderline epithelial tumors.

Conclusion

Ovarian cystic lesions are commonly encountered surgical specimens. They often present as a mass lesion so it is difficult to categorize them as non-neoplastic or neoplastic based on clinical, radiological or surgical findings. Histopathological examination is needed to diagnose these lesions and to categorize them for proper treatment. In cases of benign functional cysts spontaneous resolution may take place so symptomatic treatment and observation may help minimize surgery in these patients.

Ethical Consideration : All procedures performed were in accordance with the ethical standard of institution.

Source of Funding : Self

Conflicts of Interest : Nil

References

- Rosai J. Ovary. In: Ackerman's Surgical Pathology 9th ed. Missouri: Mosby Elsevier; 1997; 2: 1649-1736.
- Vessey, M. et al. Vessey M, et al. Ovarian neoplasms, functional cysts and oral contraceptives. Br Med J 2009; 294:1518-20
- Spanos, W. J. Preoperative hormonal therapy of cystic adnexal masses. Am J ObstetGynecol 2011; 116:551-6
- Modesitt SC, et al. Risk of malignancy in unilocular ovarian cystic tumors less than 10 centimeters in diameter. ObstetGynecol. 2003; 102(3): 594-9.
- Pudasaini S, et al. A study of ovarian cyst in a tertiary hospital of Kathmadu velly Nepal. Med Coll J 2011; 13(1): 39-41
- Zaman S, et al. A retrospective Study of Ovarian tumours and tumour-like Lesions. J Ayub Med Coll Abbottabad 2010; 22(1)
- Maliheh A, et al. Surgical Histopathology of Benign Ovarian Cysts: A Multicentre Study. Iranian Journal of Pathology 2010; 5(3): 132-6
- Cohen M, et al. Sites of endometriosis. Rev Prat 1990; 40: 1091-6
- Bhattacharya MM, et al. A clinicopathological analysis of 270 ovarian tumors. J Postgrad Med 1980; 26:103
- Gupta N, et al. Retrospective and prospective study of ovarian tumours and tumour-like lesions. Indian Journal of Pathology & Microbiology 2007; 50(3):525- 52
- Jha R, et al. Histological pattern of ovarian tumors and their age distribution. Nepal Med Coll J 2008; 10(2): 81-5
- Mondal SK, Et al. Histologic pattern, bilaterality and clinical evaluation of 957 ovarian neoplasms: A 10-year study in a tertiary hospital of eastern India. J Can Res Ther 2011; 7:433-7 [serial online] 2011 [cited 2014 Jan 3];7:433-7
- Iqbal J, et al. Pattern of Ovarian Pathologies. Journal of Rawalpindi Medical College (JRMC) 2013;17(1): 113-5
- Yasmin S, et al. Clinicohistological Pattern of Ovarian Tumors in Peshawar Region. J Ayub Med Coll Abbottabad 2008; 4:20