

Preventive Effect of Glycine on 5-FU-Induced Oral Mucositis in Rats (Histological and Immunohistochemical Study)

Fatin L. Khaphi¹, Karim H.Al. Derawi², Maha K. Ibrahim³

¹Assist. Lecturer, Department of Basic Science, College of Density, Basrah University, Iraq, ²Prof., Department of Biology, College of Science, Basrah University, Iraq, ³Prof., Department of Biology, College of Science, Basrah University, Iraq

Abstract

OM is the most popular side effects of chemotherapy and it's commonly caused by 5-Fluorouracil (5-FU). This study was aimed to assess the impact of glycine as a new option of treatment on experimentally induced oral mucositis in adult male rats.

Thirty two male rats (*Rattus norvegicus*) were divided at random in to control group (8 rats), 5-FU untreated group and 5-FU-glycine treated group (12 animals each). OM model induced by chemotherapy was instituted by intraperitoneal injection of 5-FU (60 mg/kg body weight) on days 0, 5, 10, 15 and the dorsal tongue was scratched (days 3, 4) by needle with gauge 18 to induce mucositis. The rats in treated group were received a 2mg/kg intraperitoneal injection of 5% glycine daily (day 0-20). All rats were scarified at day 21, dorsal tongue mucosa sample was removed, prepared and examine by using histological and immunohistochemical (PCNA and BCL-2 immunostaining) analysis. Glycine can protect the dorsal tongue mucosa from 5-FU induced cytotoxicity and alleviated the associated damage. In 5-FU/glycine group, both of the PCNA and BCL-2 immune expression was significantly increased ($p \leq 0.05$) in comparison with 5-FU untreated group.

Glycine provides protection toward 5-Fluorouracil induced tongue mucositis. It show fast epithelial propagation and wound healing through its antioxidant, anti-inflammatory and cytoprotective features.

Keywords: Glycine, 5-FU, Oral mucositis, PCNA, BCL-2.

Introduction

Oral mucositis (OM) is describe as mucosal barrier damage as result of desolation of its mucosal epithelium or suppression of its growth leading to change of the safety and function of oral cavity. It may become visible anyplace within the mouth but are regularly determine on cheeks, interior of lower lip or on the sides or base of the tongue¹. It can induce many complexity via

extremely painful for the patients and limiting their ability to eat, drink, talk and swallow problems to sever pain of ulcer more than infection³. Lastly menacing to life style of patients because of lower their dietary status with elevated their financial burden and exacting to their hospitalization^{4,5}. Several factors can induce OM like 5 fluorouracil (5-FU) is one of the most debilitating side effects of chemotherapy remedy as well as, radiotherapy and various forms of shock as chemical and mechanical incitation of mucosa⁶. 5-Flourouraci (5-FU) is an anti-metabolite cytotoxic drug labor by blocking fundamental biosynthetic processes or by way being integrated in to macromolecules, including RNA and DNA. The mechanism action of its cytotoxicity has been attributed to the misincorporation of fluornucleotides in to RNA and DNA and to the suppression of thymidylate synthase enzyme, a critical enzyme in nucleotide metabolism⁷.

Corresponding Author:

Karim H.Al. Derawi

Prof., Department of Biology, College of Science,
Basrah University, Iraq

e-mail: karim.thamir @ uobasrah.edu.iq

5-FU is broadly indicated for remedy of malignant tumors, particularly of the breast, colon, hepatic, pancreatic, gastric, ovarian and bladder carcinomas⁸. The employ of 5-FU is one of the most popular causes of oral mucositis. Glycine, a simple amino acid, is providing a new selection in the treatment of mucositis. It has been demonstrated to have anti-inflammatory, immunomodulatory and cytoprotective effects in various experimental models⁹. Protective effect of glycine on inflammatory lesions has been shown in different trail models. For instance, glycine is a potent restraint of resident liver macrophages and acts through a glycine-gated chloride channel¹⁰. Furthermore, administration of glycine in a rat model of ischemic-reperfusion damage resulted in down regulation of cell apoptosis and the expression of pro-apoptotic genes¹¹. So, glycine has been shown to have affirmative impacts on numerous of the paths concerned in the pathogenesis of OM. for this reason, the present study was designed to evaluate the impacts of glycine on experimentally induced oral mucoitis in rats model. Histopathological and immunohistochemical fulfillments were used to elucidate its effect on cellular proliferation and cell apoptosis.

Materials and Method

Thirty two adult male rats (*Rattus norvegicus*) with weight about 200-250 g were provided and care in the animal house of college of Science, Basra University, Iraq. The animals were kept below a typical laboratory conditions, pallat common nutrition and water ad libitum with a 12\12 hrs light \dark cycle.

Induction of OM: Oral mucositi was induced according to protocol suggested by Sonis et al¹². In brief, 60 mg/kg of chemotherapy drug 5-FU (Sigma-Aldric,UK) was injected intraperitoneal (IP) to each animal study on days 0, 5, 10 and 15. The tongue mucosa was irritated by external superficial scratches with tip of an 18-G needle on days 3 and 4 to trigger mucositis.

Experimental Design: The animals were divided randomly in three groups:

Group A: (Control Group)

8 Rats served as rats control.

Two experimental groups each of 12 rats, the two experimental groups were received intraperitoneal injection of 5-FU (60 mg/kg body weight) on days 0, 5, 10, 15 and the tongue mucosa was scratches with tip of

an 18-mesure needle on days 3, 4.

Group B: (5-FU group): Untreated group extradited normal saline intraperitoneally.

Group C: (5-FU treated with glycine): The animals were received a 2 mg/g of body weight IP injection of glycine (BDH, England), diluted in saline 5%¹³. Treated with glycine was started on day 0, with usage once time\ day in the morning until the end of experiment on day 20. All rats were sacrificed at day 21; cross section of dorsal surface of tongue mucosa was removed and designed for histological examination and immunohistochemical analysis by PCNA and BCL-2 immunolabeling.

Light microscopic method: Dorsal surface of rats tongue mucosa samples fixed in 10% formalin for 24 hours, and then the specimens were regularly processed for embedding in paraffin by typical paraffin embedding method. Sections were cut at 5 μ m, processed and then stained with Hematoxylin and eosin staining (H & E)¹⁴. Another sections positioned on top of positively charged slides for immunohistochemical revealing of anti-proliferating cell nuclear antigen (PCNA) and BCL-2 (15).

Immunohistochemical studies:

Immunohistochemical staining for revealing anti-proliferating cell nuclear antigen (PCNA), which was achieved by a monoclonal Mouse anti-PCNA clone pc 10, Dako, Denmark, and a monoclonal Mouse anti-Human BCL-2 Oncoprotein Clone 124 Code No. 1587 prepared to use N-series primary antibody, for employ with Dako EnVision TM, EnVision TM double staining and LASAB TM 2 systems. The staining method sections follow the directives included with all detection system used. Negative and positive controls were used through the study and run concurrently with all biopsy samples. PCNA positive cells expressing were recognized by brown nuclei, whereas BCL-2 positive cells expressing were showed brown cytoplasmic staining.

For analysis, 5 sections were randomly selected for each animal. About 1000 cells from cell population were counted by two watchers to make certain the topicality of analysis at a magnification of 400 X (Olympus, Japan). Finally, the percentages of PCNA and BCL-2 positive cells were calculated. The level expression of PCNA and BCL-2 was estimated depending to the scoring system of Seleit et al (16). The appliance of this system gives a score ranging from 0-3 for each degree of positivity

stained cells as (negative: < 1%, mild: 1-10%, moderate > 10- 50%, strong: > 50%). For statistical analysis Anova one way test was employed to compare the results, P value less than or equal to 0.05 ($P \leq 0.05$) was considered statistically significant.

Results

Histological Results: Microscopic observation of dorsal tongue of the control rats (group A) showed normal form and organization. The dorsal surface of tongue displayed conical, slender filiform papillae cornified with tapered tips, normal connective tissue within papillae and smooth keratinized epithelial covering, the section revealed to well defined fungiform papillae with test buds. The tongue composed mainly from interlacing bundles of striated muscle fibers that run in different directions and cross one another (fig. 1). In 5-FU untreated group (group B), the dorsal surface of tongue

revealed hyperkeratosis, severe atrophy of most filiform papillae with degenerated fungiform papillae, beneath few shallow epithelial rete ridges that invaginated deeply within the mucosa, severe inflammatory cells in the lamina propria, basal layer and supra basal with vacuolated cells specially that surrounded the papillae with shown no clear boundaries and atrophy of most muscle fibers (fig. 2). In 5-FU group treated with glycine (group C), the epithelial layer revealed to an increase in the thickness with re-epithelization of stratified squamous epithelium and vacuolated keratinocytes observed. Also, some of filiform papillae restored the normal shape with tapered tips and cornified, well developed fungiform and circumvallate papillae observed with test buds. Restoration of most normal rete ridges and inflammatory characteristics were still notable in the lamina propria (fig. 3).

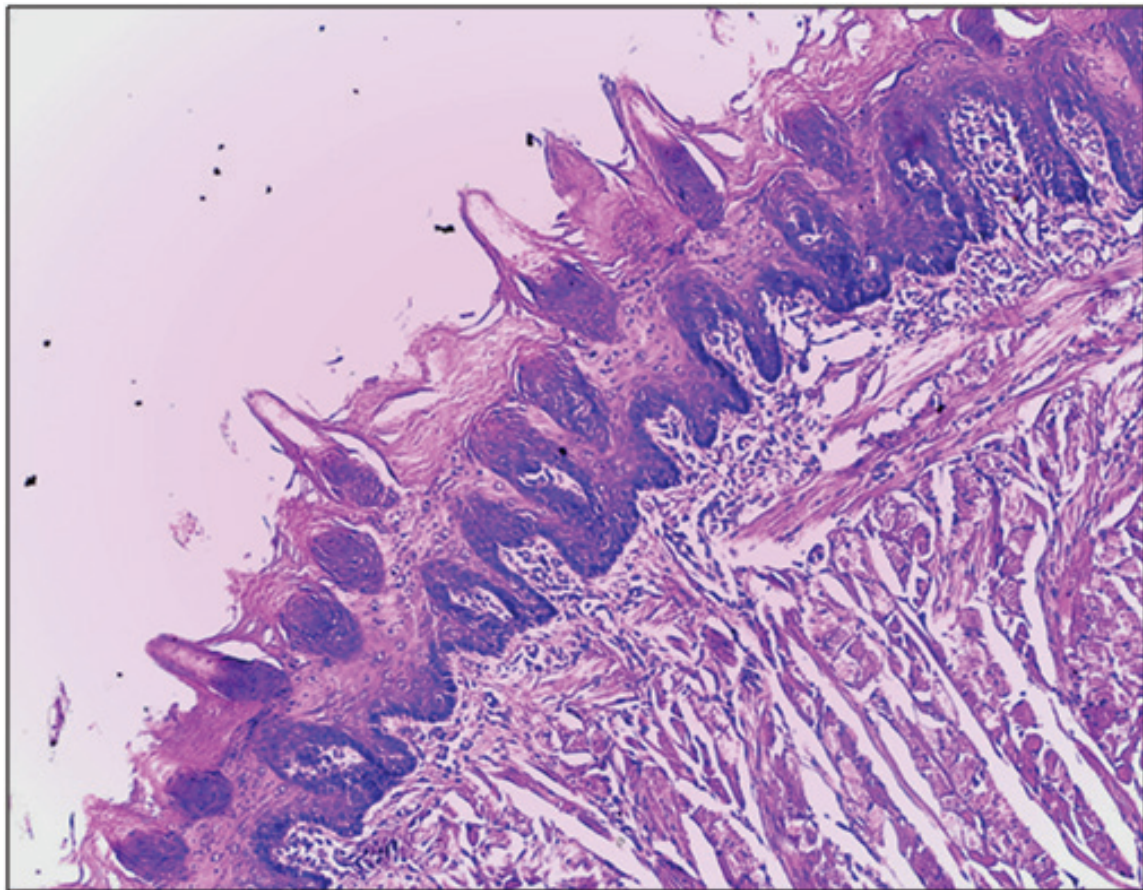


Figure (1): Section of dorsal tongue mucosa of rats in control showed normal filiform () and fungiform papillae (), papillated lamina propria () and normal bundles of striated muscles () (H & E x10).

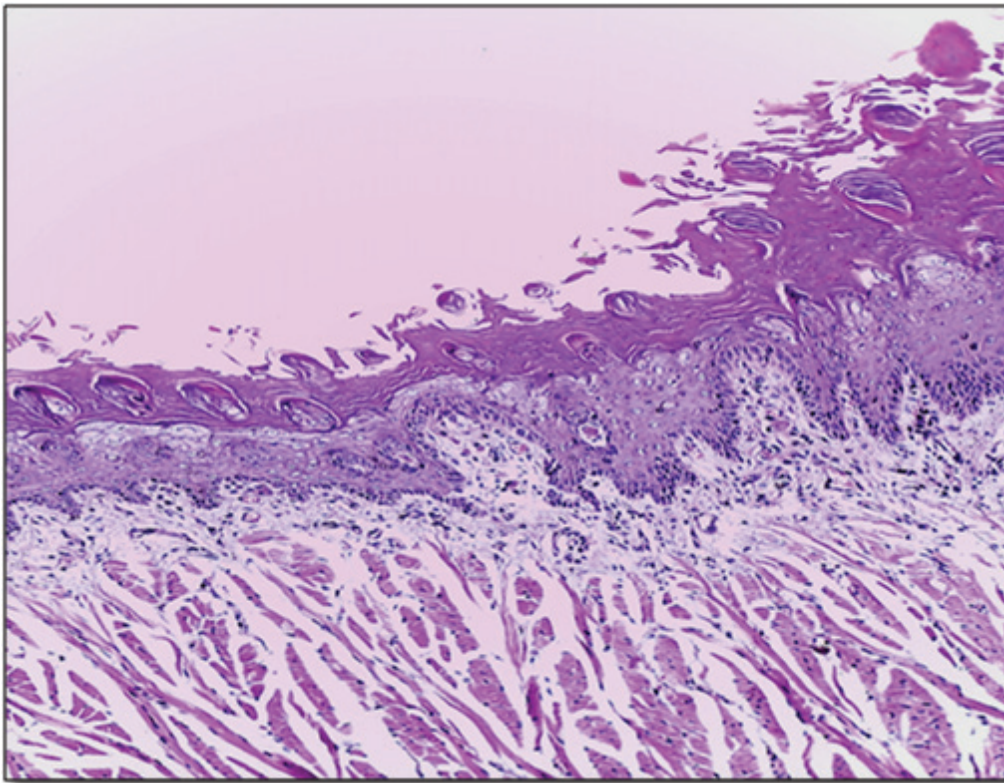


Figure (2): Section of dorsal tongue of rats from (group B) showing hyperkeratosis (), sever damage in filiform papillae (), shallow rete ridges (), sever inflammatory cells (head arrow) and atrophied muscle fibers () (H & E x10).

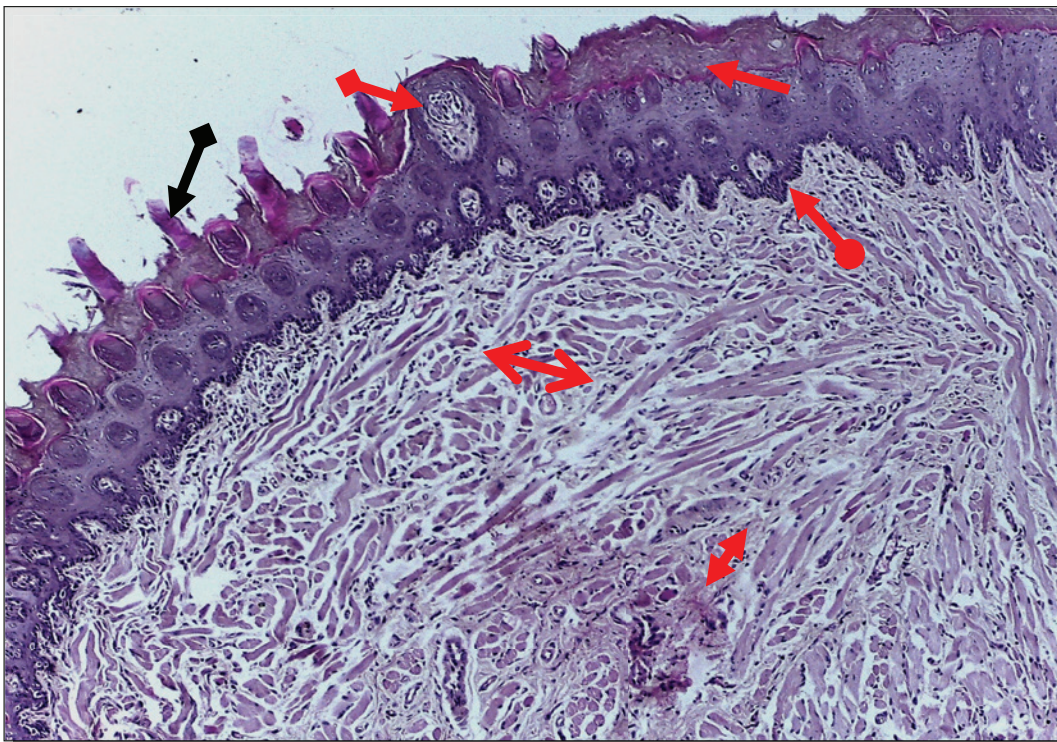


Figure (3): Section of dorsal tongue mucosa of rats from group C showing re-epithelization (), some of filiform papillae restored the normal shape (), well developed fungiform () and circumvallate papillae (), still mild inflammatory cells () with strand of irregular striated muscle fibers () H & E, x100

Immunohistochemical detections: The photograph of dorsal surface of rats tongue in group A (control group) showed strong positive immune expression to PCNA was observed in the nuclei of basal and supra basal layers within tongue mucosa (fig.4). While, the immunoexpression of PCNA in group B was revealed mild immune reactivity reserved at the basal cells within nucleus and some of keratinocytes at surface layer (fig. 5). As for group C, it was recognized that PCNA immunostaining was moderate immune reactivity comprising the whole basal layer cells of tongue epithelium; also few positive cells of connective tissue were noticed (fig. 6). Furthermore,

the immunoexpression of BCL-2 protein in normal rat tongue mucosae (group A) showed mild cytoplasmic reactions of some epithelial cells at surface of epithelium. In group B, the immunoexpression of BCL-2 revealed negative immunoreactions in the whole of epithelial cells. Also, the cells of lamina propria showed negative BCL-2 immunolabeling. The immunoexpression of BCL-2 of group C showed that positive immunostaining of BCL-2 was greatly than the control limited to keratinocytes of epithelial surface layer and also some cells of basal and Para basal layer.

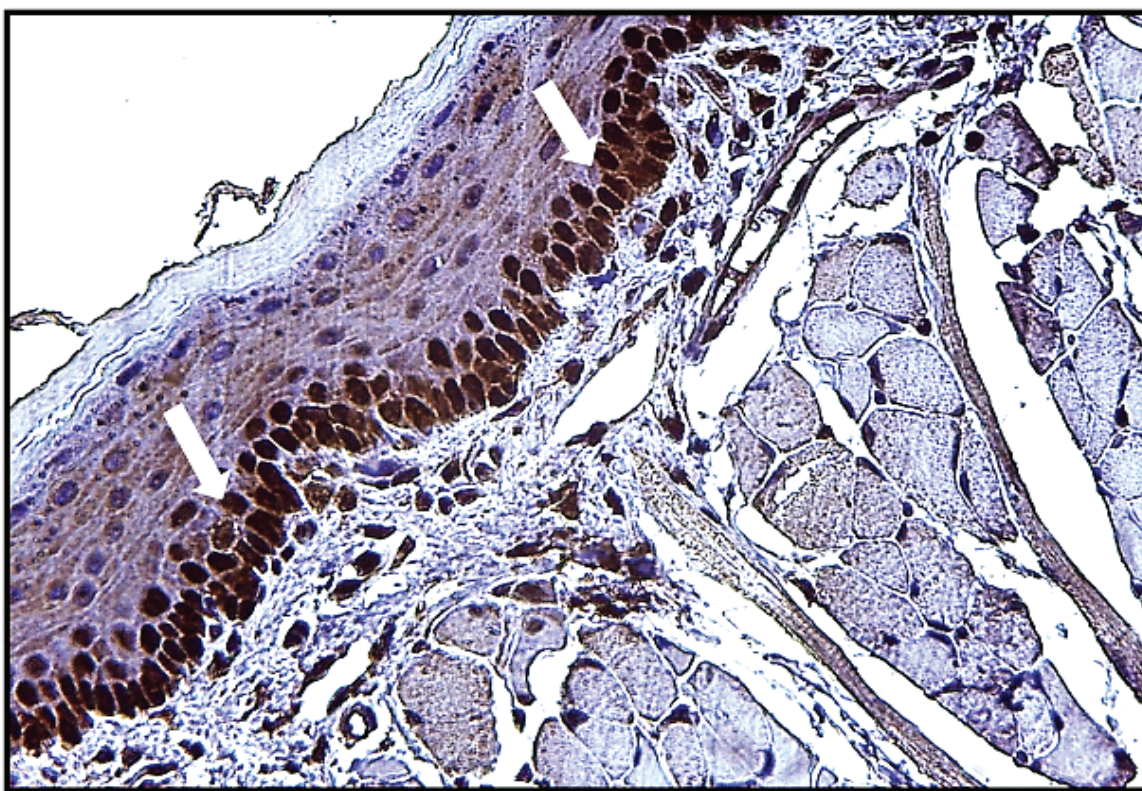


Figure (4): Section of dorsal tongue mucosa of rats from group A showing strong brown PCNA positive nuclei in the basal and supra-basal layers of the tongue epithelium (arrow) (immunohistochemistry. X400).

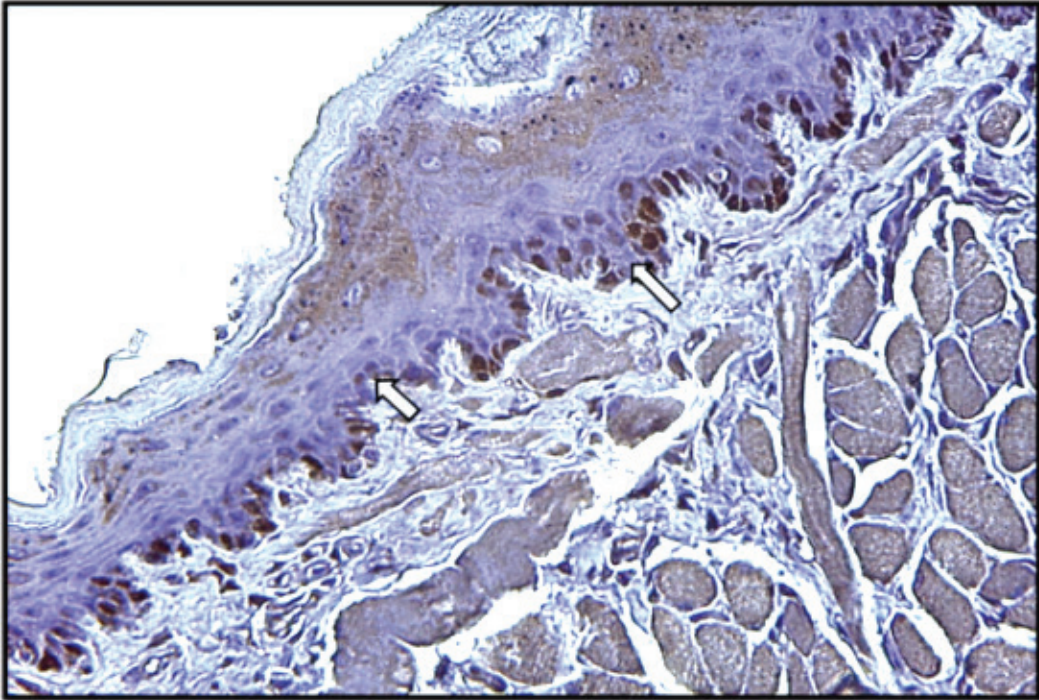


Figure (5): Section of dorsal tongue mucosa of rats from group B showing mild staining to PCNA at basal cells with missing the positive cells in some basal layer cells (arrows) (immunohistochemistry X400).

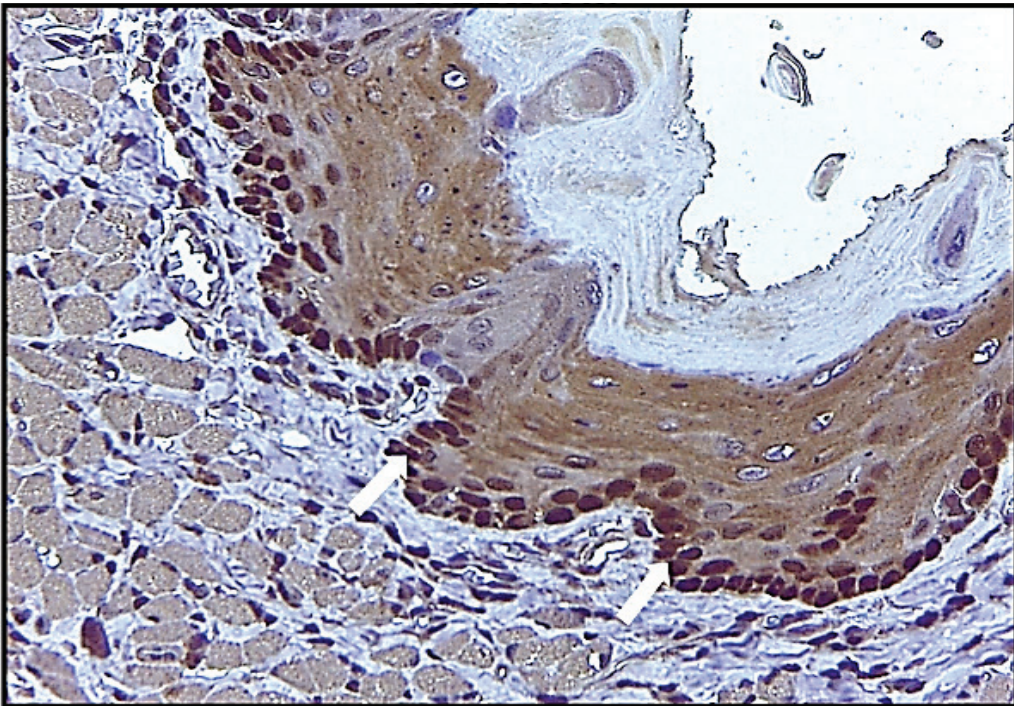


figure (6): Section of dorsal tongue mucosa of rats from group C showing positive staining cells of basal layer (arrows) (immunohistochemistry X400).

Regarding to Statistical analysis, the immune expression of PCNA in the control group was showed 16.32 ± 0.16 while BCL-2 in the same group 7.27 ± 0.10 . ANOVA test was showed a significant decrease ($P=0.000$) of mean immune expression in the 5-FU treated group in both of PCNA and BCL-2 were 4.71 ± 0.08 and 0.07 ± 0.05 respectively, in comparison with control group. The treatment with glycine causes a significant increase in the number of PCNA and BCL-2 positive cells 10.85 ± 0.08 and 3.21 ± 0.07 respectively, in comparison with the 5-FU treated group ($p \leq 0.05$).

Discussion

Oral mucositis is a complex process started through damage to cells in the basal epithelium and fundamental tissue of oral mucosa and has recurrent painful obstacles related with mucosal damage¹⁷. As well, this complex process comprising not only direct cell damage happened by chemotherapy or radiotherapy, but also a complex cascade of biological proceedings¹⁸. Administration of 5-FU has been accomplished like a technique to trigger oral mucositis in rats and the initiation of lesion appeared through five to seven days of their administration, so the mouth becomes prepared for entry of microbes. Therefore, the oral mucosa becomes vulnerable to an increased risk of infection and ulceration^{19,20}. Different histological changes as hyperkeratosis, flattening of rete ridges, sever inflammatory cells in lamina propria and severe atrophied in papillae were seen associated with use of 5-FU, perhaps because of the mechanism of suppression of epithelial proliferation by cytotoxic effect of 5-FU. Also, administration of 5-FU was joined by a significant reduction in PCNA and BCL-2 positive cells. Reactive oxygen species is generated by chemotherapy which is harmful to the DNA of epithelial cells and reduce the metabolism in progenitor cells and give rise to inhibition of mitosis and raise of apoptosis²¹. These results were clarified and supported the findings of some investigators²², were reported that nutritional supplementation with 5% glycine has accelerated the process of wound healing, recover the weight gain, antioxidant ability and immunity. The anti-inflammatory impacts of glycine are supposed to be mediated, because of its method of action in the cell membrane where it stimulates the chloride channel that stabilizes the membrane possible²³. Furthermore, glycine prevents the raise of intracellular calcium which stimulates the forming of the cytokines by suppressing cells that activate the inflammatory method through preventing stimulation of TNF- α and NF- κ B and therefore reducing

the production of free radicals and additional toxic mediators²⁴. PCNA is localized in the nucleus and is related with cell proliferation²⁵.

Financial Disclosure: There is no financial disclosure.

Conflict of Interest: None to declare.

Ethical Clearance: All experimental protocols were approved under the College of Science and all experiments were carried out in accordance with approved guidelines.

References

1. Mahdi AK, Al-Falahi NH and Nahi HH. Effects of chitosan and hyaluronic acid in healing of chemically induced oral ulcer in rabbits. *Kufa Journal for Veterinary Medical Sciences*. 2016; 7: 138-151
2. Al-Refai AS. Immunohistochemical study of the effect of chamomile extract on 5-fluorouracil induced intestinal mucositis in albino rats. *J.Clin. Cell Immunol*. 2014; 5:1-10.
3. GANDHI K, DATTA G, AHUJA S. Prevalence of Oral Complications occurring in a Population of Pediatric Cancer Patients receiving Chemotherapy. *Int J Clin Pediatr Dent*. 2017; 10: 166-171.
4. Alvarino C, Sarrion-Perez MG. Prevention and treatment of oral mucositis in patient receiving chemotherapy. *J Clin Exp Dent*. 2014; 6:e74-80.
5. Al-Refai AS. Chemoprotective effect of ascorbic acid on cyclophosphamide induced oral toxicity. *Zanco J. Med. Sci*. 2017;21:1540-1551.
6. Koizumi R, Azuma K, Izawa H, Morimoto M, Ochi K, Tsuka T, Imagawa T, Osaki T, Ito N, Okamoto Y, Saimoto H and Ifuku S. Oral Administration of Surface-Deacetylated Chitin Nanofibers and Chitosan Inhibit 5-Fluorouracil-Induced Intestinal Mucositis in Mice. *Int J Mol Sci*. 2017; 18.
7. Longley DB, Harkin DP, Johnston PG. 5-fluorouracil: mechanisms of action and clinical strategies. *Nat Rev Cancer*. 2003; 3: 330-338.
8. Mead GM. Management of oral mucositis associated with cancer chemotherapy. *Lancet*. 2002; 359: 815-816.
9. Wang W. Glycine metabolism in animals and humans: implications for nutrition and health. *Amino Acids*. 2013,45: 463-477.

10. Wheeler M, Stachlewitz, R, Yamashina S. Glycine-gated chloride channels in neutrophils attenuate calcium influx and superoxide production. *FASEB Journal*. 2000; 14: 476-484.
11. Jacob T, Ascher E, Hingorani, A. Glycine prevents the induction of apoptosis attributed to mesenteric ischemia-reperfusion injury in a rat model. *Surgery*. 2003; 134: 457-466.
12. Sonis ST, Tracey C, Shklar G, Jenson J, Florine D. An animal model for mucositis induced by cancer chemotherapy. *Oral Surg Oral Med Oral Pathol*. 1990; 69: 437-443.
13. Sa O, Lopes N, Alves M. Glycine supplementation reduces the severity of chemotherapy-induced oral mucositis in hamsters. *Natural Science*. 2013;5(9):972-978.
14. Bancroft JD, Layton C. The hematoxylin and eosin, connective mesenchymal tissues with their stains. In: Suvarna SK, Layton C and Bancroft JD, editors. *Bancroft's Theory and practice of histological techniques*. 7th edition. Churchill Livingstone: Philadelphia. 2013; 173- 212 & 215-238.
15. Jackson P, Blythe D. Immunohistochemical techniques [chapter 8]. In: Suvarna SK, Layton C, Bancroft JD, editors. *Theory and practice of histological techniques*. 7th ed. Philadelphia: Churchill Livingstone of Elsevier. 2013; 381-434.
16. Seleit IA, Asaad N, Maree A, Abdel Wahed M (2010) Immunohistochemical expression of p53 and Ki-67 in cutaneous lupus erythematosus. *J Egypt Women Dermatol Soc* 7: 5-15.
17. Ahmed KM, Talabani N, Altaei T. Olive leaf extract as a new topical management for oral mucositis following chemotherapy: a microbiological, examination, experimental animal study and clinical trial. *Pharmaceut. Anal. Acta*. 2013; 4:1-18.
18. Sonis S. new thoughts on the initiation of mucositis. *Oral Diseases*. 2010; 16: 597-600.
19. LotfyAO, Zayed M. Immunohistochemical study of the effect of *Nigella Sativa* L extract on chemotherapy induced oral mucositis in albino rats. *Cairo Dental Journal*. 2009; 25:159:166.
20. Won JH, Ji JE, Ahn KH, Kim SK, Choi JM, Ha HC, Kim HM, Yun CK, Han K and Kim DK. Effect of rice cell-derived human granulocyte-macrophage colony-stimulating factor on 5-fluorouracil-induced mucositis in hamsters. *Biol Pharm Bull*. 2013; 36:425-31.
21. Sonis ST. Pathobiology of mucositis. *Semin Oncol Nurs*. 2004; 20: 11-15.
22. Xie S, Zhou W, Tian L, Niu J, Liu Y. Effect of N-acetyl cysteine and glycine supplementation on growth performance, glutathione synthesis, anti-oxidative and immune ability of Nile tilapia, *Oreochromis niloticus*. *Fish Shellfish Immunol*. 2016; 55:233-41.
23. Hartog A. Anti-inflammatory effects of orally ingested lactoferrin and glycine in different zymosan-induced inflammation models: Evidence for synergistic activation. *International Immunopharmacology*. 2007; 7: 1784-1792.
24. MaurizB, Matilla J, Culebras M. Dietary glycine inhibits activation of nuclearfactor kappa B and prevents liver injury in hemorrhagic shock in the rat. *FreeRadical Biology & Medicine*. 2001; 31: 1236-1244.
25. Aboushady IM, Mubarak RT, El-mougy S, Rashed L, El-desouky AA. The effect of transplanted bone marrow stem cells on the tongue of irradiated rats (Histological and Immunohistochemical study). *J Am Sci* 2012; 8 (11):553-61.