

Isoniazid Mono Resistance: Changing Trends in Drug Resistant Pulmonary Tuberculosis. – A Case Series of 3 Patients

Arti D. Shah¹, Anchal Jain², Apoorva³, Kusum V. Shah⁴, Yash Rana⁵, Saket kumar⁶

¹Professor and Head of Department, ²3rd year Post Graduate Resident, ³3rd year Post Graduate Resident, ⁴Professor, ⁵Assistant Professor, ⁶3rd year Post Graduate Resident, Department of Respiratory Medicine, Smt. S.B.K.S. Medical Institute & Research Centre, Sumandeep Vidyapeeth Deemed to be University, Piparia (Vadodara)- 391760 (India)

Abstract

Drug resistant tuberculosis is a major public health concern in many countries including India, Isoniazid resistance (INH) accounts for 7.2 % of new cases globally.¹ In our case series 3 patients had INH mono resistance out of which 2 patients had no previous history anti tuberculosis therapy (ATT). All 3 patients received 6 months of standard regimen under National Tuberculosis Elimination Programme (NTEP). All patients showed clinical improvement. INH mono resistance diagnosis is often delayed due to lack of infrastructure of 1st line probe assay (LPA) at various centres. INH mono resistance if diagnosed early can also help in prevention of Multi drug resistant tuberculosis (MDR TB).

Keywords : INH mono resistance, LPA, MDR TB.

Introduction

Drug resistant tuberculosis is a major public health concern in many countries including India. In 2018 an estimated 3.4 % of new cases and 18 % of previously treated cases had MDR TB worldwide.¹ India contributes to 27 % of MDR TB cases worldwide. The global average of INH resistance without concurrent rifampicin resistance is 7.2 % in new cases and 11.6 % in previously treated TB cases.¹ However treatment is mainly focussed on MDR TB as all cases of rifampicin resistance are considered as MDR TB until proven otherwise. A TB patient can be labelled as INH mono resistance only after documented rifampicin susceptibility has been established. This can be achieved only through 1st line LPA or through culture drug susceptibility testing (DST). It is because of absence of rapid testing for INH

resistance effective regimen is delayed and is associated with higher treatment failure.²

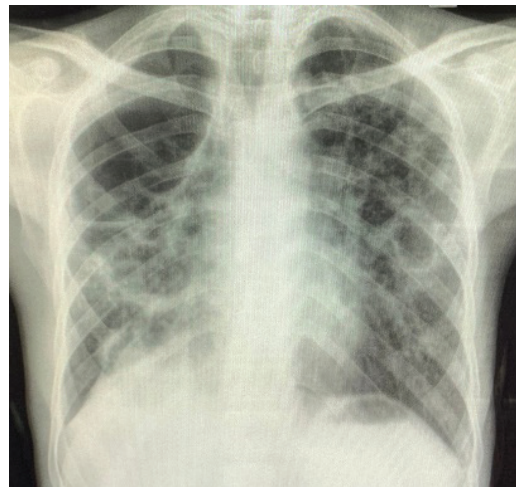


Figure 1 : Chest x ray PA view showing bilateral upper zone cavities.

Case 1 : A 38 years old non immunocompromised male presented to us with complaints of dry cough, diffuse chest pain and significant weight loss for past 2 months. He had bilateral upper zone cavity on chest x ray posteroanterior (PA) view (figure 1). His induced

Corresponding Author :

Dr . Anchal Jain

Email id : aanchalj49@gmail.com

Contact No. : +91 8290318690

sputum was 1+ for acid fast bacilli (AFB) on sputum microscopy and rifampicin resistance was not detected on cartridge based nucleic amplification test (CBNAAT). He was started on 4 drugs regimen consisting of isoniazid (H), rifampicin (R), pyrazinamide (Z) and ethambutol (E). Patient came back after 3 weeks with worsening of symptoms and now presented with productive cough. His first line LPA was sent which showed INH mono resistance. Then he was started on 4 drugs consisting of R,Z,E and Levofloxacin (Lfx) for 6 months. At the end of 2 months his sputum converted to negative for AFB and showed significant clinical improvement.

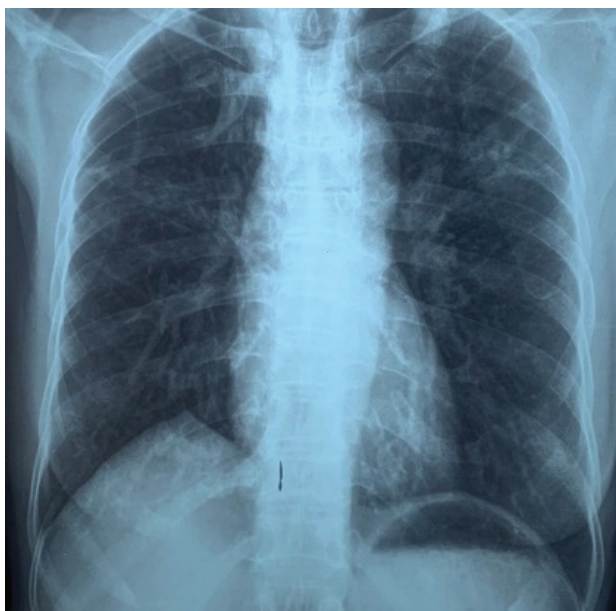


Figure 2 : Chest x ray PA view showing left upper zone cavitory lesion.

Case 2 : A 50 years old non immunocompromised female presented to us with complaints of productive cough, loss of appetite and significant weight loss for past 1 month. She had history of pulmonary TB (PTB) 20 years back for which she was treated with ATT for 6 months. She had left upper zone cavitory lesion on chest x ray PA view (figure 2). Her sputum was 3+ positive for AFB on sputum microscopy. Her sputum sample was sent for CBNAAT and 1st line LPA. She was started on 4 drugs regimen consisting of H,R,Z,E. Her sputum CBNAAT showed no resistance for rifampicin but 1st line LPA showed INH mono resistance. Her treatment regimen was changed to R,Z,E and Lfx for 6 months. At the end of 2 months her sputum was negative for AFB and showed clinical improvement.

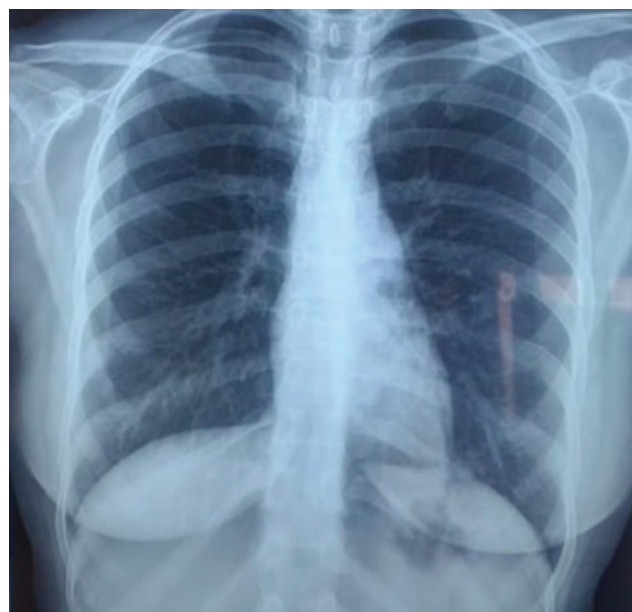


Figure 3 : Chest x ray PA view is showing left lower zone cavitory lesion.

Case 3 : A 20 years old HIV negative female presented to us with complaints of diffuse chest pain, loss of appetite and productive cough for past 20 days. She was a known case of sickle cell disease. Her chest x ray PA view showed left lower zone cavitory lesion (figure 3). She was sputum positive for AFB on sputum microscopy and her sputum 1st line LPA showed INH mono resistance while sputum CBNNAT indicated no rifampicin resistance detected. She was started on 4 drugs regimen consisting of H,R,Z,E and was later changed to 6 months of R,Z,E and Lfx. She was sputum negative at the end of treatment and had clinical improvement.

Discussion

In the past INH mono resistance was detected through culture based DST and H resistance was determined at lower and higher concentrations. It is important because if H resistance is present at lower concentration and the TB bacilli is susceptible at higher concentration it can still be used to treat INH mono resistance. But this has not been established in clinical trials.³ 50 % to 95 % of INH resistant strains contain mutations in codon 315 WT1 of *KatG* gene and can be detected on 1st line LPA.⁴ *KatG* mutations are thought to cause high level INH resistance whereas low level resistance is caused by *InhA* mutations.⁵ In our case series we have presented 3 cases of INH mono resistance. 1st case diagnosis was delayed as he was thought to have drug sensitive TB based on his history and sputum microscopy. His diagnosis was

further delayed as sputum 1st line LPA is available only after 3 weeks at our institute. He showed significant improvement once he was started on latest INH mono resistance regimen under NTEP. In our 2nd case drug resistance was suspected as she had history of ATT intake in the past. She was started on drug susceptible anti TB drugs as we had no information regarding her resistance pattern and was deteriorating clinically. She was put on 4 drugs regimen for INH mono resistance. In our 3rd case also we ordered for 1st line sputum LPA based on our previous experience. She also improved clinically after being started on INH mono resistance regimen. In 2018 WHO released guidelines for treatment of INH mono resistance. It recommends 6 months of R,Z,E and Lfx in patients with INH resistance with confirmed rifampicin susceptibility. WHO recommends Lfx over moxifloxacin because of drug interaction with rifampicin.⁶ A 2017 systematic review and meta-analysis on treatment of INH resistant TB with 1st line ATT drugs suggests that such regimens can be suboptimal and lead to treatment failure, relapse or both.⁷

Conclusion

Primary INH mono resistance is on the rise as has been suggested in two of our cases and by their WHO global report 2019. All INH resistant patients must receive 4 drugs treatment regimen as suggested by WHO and NTEP for proper cure and improvement of patients. All INH resistant patients must be closely followed for development for MDR TB. Early diagnosis and treatment is key to management of INH mono resistance.

Ethical Clearance- Taken from SVIEC committee (letter attached)

Source of Funding- Non funded.

Conflict of Interest - Nil.

References

1. World Health Organization. Global Tuberculosis Report 2019. Geneva, Switzerland: World Health Organization; 2019.
2. Olson G, Nathavitharana RR, Lederer PA. Diagnostic Delays and Treatment Implications for Patients with Isoniazid-Resistant Tuberculosis: A Case Report and Review of the Literature. *Open Forum Infect Dis*. 2019; 6 (6) : 222, 2019.
3. Lempens P, Meehan CJ, Vandellannoote K, et al. Isoniazid resistance levels of Mycobacterium tuberculosis can largely be predicted by high-confidence resistance-conferring mutations. *Sci Rep* 2018; 8:3246.
4. Ando H, Kondo Y, Suetake T, Toyota E, Kato S, Mori T, et al. Identification of katG mutations associated with high-level isoniazid resistance in Mycobacterium tuberculosis. *Antimicrob Agents Chemother* 2010;54:1793-9.
5. Bollela VR, Namburete EI, Feliciano CS, Macheque D, Harrison LH, Caminero JA. Detection of katG and inhA mutations to guide isoniazid and ethionamide use for drug-resistant tuberculosis. *Int J Tuberc Lung Dis* 2016; 20:1099–104.
6. World Health Organization. WHO Treatment Guidelines for Isoniazid-Resistant Tuberculosis: Supplement to the WHO Treatment Guidelines for Drug-Resistant Tuberculosis. Geneva, Switzerland: World Health Organization; 2018.
7. Gegia M, Winters N, Benedetti A, van Soolingen D, Menzies D. Treatment of isoniazid-resistant tuberculosis with first-line drugs: a systematic review and meta-analysis. *Lancet Infect Dis* 2017; 17:223–34.