

# Morphometric study of Macewan's Triangle in Relation to Depth of the Sigmoid Sinus Plate

**Senthil Kumar. B**

*Assistant Professor in Anatomy / Head – Central Research Laboratory for Biomedical Research, Vinayaka Mission's Kirupananda Variyar Medical College and Hospital, Vinayaka Mission's Research Foundation (Deemed to be University) Salem, TamilNadu, India.*

## Abstract

**Background:** The suprameatal triangle is used for approaching the tympanic cavity and also it is an important landmark for otologic surgeons during mastoidectomy.

**Aim:** To determine the depth of sigmoid sinus plate over the Macewan's triangle by morphometry of various anatomical landmarks.

**Materials & Methods:** The study was carried out in the Department of Anatomy, Penang International Dental College & VMKV Medical College, Salem on 30 dry human adult skulls. Five landmarks (D1, D2, D3, D4, D5 and D6) were taken on the left and right sides of the skulls and the imaginary lines were constructed and measured by Vernier caliper between the landmarks.

**Results:** The measurement of D2 showed statistically significant differences. The correlations of D1, D3, D4, D5 and D6 on both sides do not show any significant differences. The linear correlation equations were derived using the measurements for predicting D6.

**Conclusion:** The depth of sigmoid sinus plate (D6) can be assessed using D1, D2, D3, D4, D5 on lateral view of head & neck X-rays which can be used by Otologist during mastoidectomy to avoid severe bleeding complications from sigmoid sinus.

**Keywords -** Henle's spine, Suprameatal triangle, Mastoidectomy, Sigmoid sinus,

## Introduction

The Macewan's triangle or suprameatal triangle is an important surgical landmark for mastoidectomy. It is used by surgeons as an anatomical landmark to locate

the mastoid antrum of the mastoid process. Suprameatal triangle is present above external acoustic meatus of the temporal bone. The triangle is related to the Henle's spine or suprameatal spine.<sup>1</sup> The suprameatal spine is crest shape in female and suprameatal depression is deeper in males than in females.<sup>2</sup> The mastoid antrum of the mastoid process is located 15 mm deeper to the suprameatal triangle of the skull.<sup>3</sup> The suprameatal triangle is bounded anteriorly by the post-superior border of the external auditory canal, superiorly by the supramastoid crest and posteriorly by a vertical line drawn tangential to the posterior margin of the external canal.<sup>4</sup>

---

### Corresponding author:

**Dr. B. Senthil Kumar,**

Assistant Professor, Department of Anatomy,  
Vinayaka Mission's Kirupananda Variyar Medical  
College and Hospital, Vinayaka Mission's Research  
Foundation (Deemed to be University)

Salem – 636308, TamilNadu, India.

Email – skdrchinu88 @ gmail.com

Telephone number – 09894398677

The supramastoid crest corresponds to the floor of middle cranial fossa. The posterosuperior margin of the

external acoustic meatus, lies over the descending part of the facial nerve canal.<sup>5</sup> The suprameatal approach can avoid the process of mastoidectomy and posterior tympanotomy.<sup>6</sup> The suprameatal approach is done by entering through retroauricular tympanotomy flap, by introducing an electrode through the tunnel drilled in the suprameatal triangle above the Henle's spine. Thus the approach is of great importance to otologic surgeons during mastoidectomy.<sup>7</sup>

The sigmoid venous sinus commences immediately below the temporal bone on both sides of the head, following a complex course by passing through sigmoid sulcus and enters the jugular foramen and continues down as the internal jugular vein. In mastoid clearance two main surgical procedures were followed that includes canal wall up and canal wall down. The sigmoid sinus acts as an anatomical marker during mastoidectomy. The anatomy of sigmoid sinus and its extent along with the depth of it from suprameatal triangle will help to prevent unwanted bleeding during surgery.<sup>8</sup>

**Aim:** To determine the depth of sigmoid sinus plate over the Macewan's triangle by morphometry of various anatomical landmarks.

### Objectives

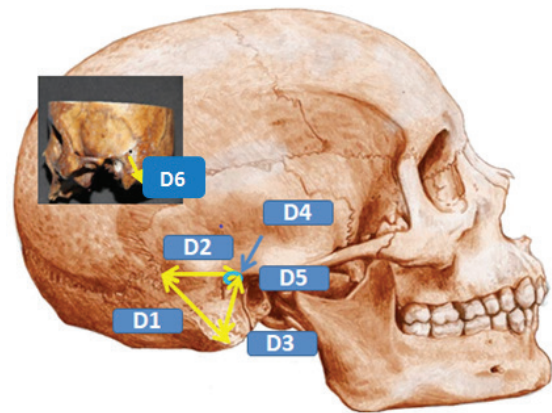
1. To correlate the surgical landmarks on the lateral surface of the mastoid bone to the sigmoid sinus plate depth.
2. To trace out the depth between the Macewen's triangle and the sigmoid sinus plate using various surgical landmarks.

### Materials and Methods

The study was carried out in the Department of Anatomy, Penang International Dental College & VMKV Medical College, Salem on 30 dry human adult skulls. The study was approved by IEC of VMKV Medical College (Reference - VMKVMC/IEC/18/52). Five landmarks were used on the left and right sides of the skulls which includes the tip of the mastoid process, the asterion, and the midpoint of the suprameatal triangle, suprameatal spine/Henle's spine and porion. Five imaginary lines, **D1**: Distance between asterion and tip of mastoid process, **D2**: Distance between asterion and midpoint of Macewen's Triangle, **D3**: Distance

between tip of mastoid to midpoint of Macewen's Triangle, **D4**: Distance between Henle's spine and midpoint of Macewen's Triangle, **D5**: Distance between porion and midpoint of Macewen's Triangle **D6**: Depth of Macewen's Triangle. To measure the depth of sigmoid sinus plate from the surface of suprameatal triangle (D6), the skull was oriented in the anatomical position (Frankfurt plane) and the drilling was done using electrical driller between surface of suprameatal triangle and the sigmoid sinus plate towards the direction of maxillary process of temporal bone along its upper border.<sup>9</sup> Skulls without any damage of Macewan's triangle, prominent suprameatal spine/ Henle's spine were included for the study.

**Figure 1 : Morphometric landmarks and Macewan's Triangle:**



**D1**: Distance between asterion and tip of mastoid process, **D2** : Distance between asterion and midpoint of Macewen's Triangle, **D3** : Distance between tip of mastoid to midpoint of Macewen's Triangle, **D4** : Distance between Henle's spine and midpoint of Macewen's Triangle, **D5**: Distance between porion and midpoint of Macewen's Triangle **D6**: Depth of Macewen's Triangle.

The association between two categorical variables was analyzed by the linear correlation between variables which was measured by Pearson correlation coefficient. P values less than the 0.05 level of significance was considered to be statistically significant. Linear regression equation was derived using excel.

### Results

D1, D2, D3, D4, D5 and D6 of adult skulls were measured on both right and left side and the average was calculated among the sides and tabulated as below

(Table1). The average of D1 (5.14±0.45 cm), D2 (3.87±0.18 cm), D3 (3.35±0.38 cm), D4 (3.27±0.14 cm), D5 (1.22±0.19 cm) and D6 (0.93±0.043 cm) of all 30 skulls on both sides (Table1).

**Table 1: Variants of D1, D2, D3, D4, D5 and D6 of adult skulls**

Variants	Right (cm)	Left (cm)	Average(cm)
D1	4.97 ± 0.58	5.30 ± 0.14	5.14±0.45
D2	3.99 ± 0.17	3.76 ± 0.11	3.87±0.18
D3	3.69 ± 0.14	3.0 ± 0.16	3.35±0.38
D4	3.29±0.15	3.26±0.12	3.27±0.14
D5	1.19 ± 0.17	1.26 ± 0.19	1.22±0.19
D6	0.93 ± 0.17	0.94 ± 0.05	0.93±0.043

Values are expressed as Mean ± SD, n = 30 with 30 on right side & 30 on left side of skull. **D1**: Distance between asterion and tip of mastoid process, **D2**: Distance between asterion and midpoint of Macewen's Triangle, **D3** : Distance between tip of mastoid to midpoint of Macewen's Triangle, **D4** : Distance between Henle's spine and midpoint of Macewen's Triangle, **D5**: Distance between porion and midpoint of Macewen's Triangle **D6**: Depth of Macewen's Triangle.

The variants of both right and left side measurements suggested the linear correlation (R value) between variables which was measured by Pearson correlation coefficient. D2 was found to be statistically significant (0.002) when compared to other variants (Table 2) (Figure 2)

**Table 2: Statistical Correlations and the probability (p values) of variants**

Variants (Right & Left)	Correlation (R value)	P value
D1	0.0918	0.529#
D2	0.42598	0.002*
D3	0.23138	0.106#
D4	0.06815	0.638#
D5	0.12874	0.373#
D6	0.00868	0.952#

n = 30 with 30 on right side & 30 on left side of skull, # - non significant, \* - significant, P value \*P<0.05, Statistical analysis – Pearson correlation coefficient. **D1**: Distance between asterion and tip of mastoid process, **D2** : Distance between asterion and midpoint of Macewen's

Triangle, **D3** : Distance between tip of mastoid to midpoint of Macewen's Triangle, **D4** : Distance between Henle's spine and midpoint of Macewen's Triangle, **D5**: Distance between porion and midpoint of Macewen's Triangle **D6**: Depth of Macewen's Triangle.

The variants of both right and left side measurements suggested the linear regression ( $R^2$  value) between variables. All variants were found to be statistically significant when compared (Table 3).

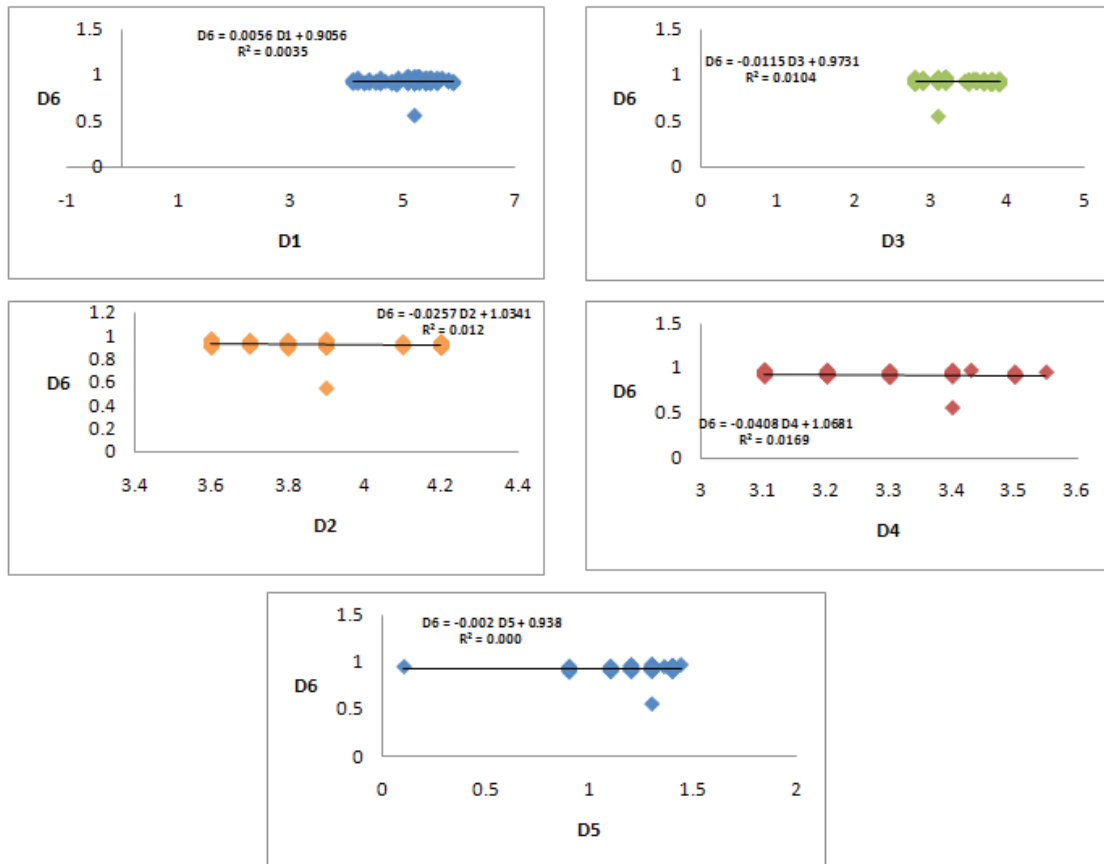
**Table 3: Linear regression and (D6) equation derived**

Linear regression (R2 Value)	Equation Derived
0.004*	$D6 = 0.0056 D1 + 0.9056$
0.012*	$D6 = -0.0257 D2 + 1.0341$
0.010*	$D6 = -0.0115 D3 + 0.9731$
0.017*	$D6 = -0.0408 D4 + 1.0681$
0.001*	$D6 = -0.002 D5 + 0.938$

n = 30 with 30 on right side & 30 on left side of skull , # - non significant,

\* - significant, P value \*P<0.05, Statistical analysis – Linear regression

**Figure 2: Linear regression and (D6) equation derivation**



**D1:** Distance between asterion and tip of mastoid process, **D2 :** Distance between asterion and midpoint of Macewen's Triangle, **D3 :** Distance between tip of mastoid to midpoint of Macewen's Triangle, **D4 :** Distance between Henle's spine and midpoint of Macewen's Triangle, **D5:** Distance between porion and midpoint of Macewen's Triangle **D6:** Depth of Macewen's Triangle.

### Discussion

The morphology and anatomy of the suprameatal triangle has more surgical importance. The knowledge is very much essential for otologic surgeons to approach the mastoid antrum.<sup>10</sup>

Sigmoid sinus is a dural venous sinus draining the brain structures. Emissary vein drains into the sigmoid sinus through the posterior condylar canal. The sigmoid sinus is related to the occipital emissary foramen which transmits a vein that connects sigmoid sinus with the suboccipital venous plexus of veins.<sup>11</sup> During mastoidectomy, there is a complication of perforating the sigmoid sinus. The perforation of sigmoid venous sinus during mastoidectomy can be prevented by calculating the depth of the sinus plate preoperatively using the equation derived.<sup>12</sup> It is very important to know the exact depth and site of sigmoid sinus. In radical mastoidectomy chances are more for damage of the sinus plate accidentally which can result in severe venous bleeding. If the depth (D6) can be calculated from D1, D2, D3 and D5 on the lateral view of plain X-rays, the dangerous complication of severe venous bleeding can be avoided. The statistical analysis of the variants suggested that there exists correlation between the depth of the sinus plate (D6) with other five parameters namely D1, D2, D3, D4 and D5.

The depth of the sigmoid sinus plate can be calculated using various measurements of D1 to D5 using X-rays with Macewen's triangle as a surgical landmark.<sup>13</sup> Many morphometric measurements were performed and reported between various surgical landmarks for the mastoidectomy.<sup>14</sup> The suprameatal approach was proved to be safer technique as it does not endanger either facial nerve or the chorda tympani nerve.<sup>15</sup>

Mohammad et al., 2011 were using D1 and D2 to estimate D3 (depth of sigmoid sinus plate), in their

study and stated a hypothesis that measuring the first two lines D1 and D2 might be an indicator to the third line D3.<sup>9</sup> Earlier studies were done only on the topographic anatomy and surgical importance of the suprameatal triangle but no further studies had mentioned the use of various landmarks of Macewen's triangle to know the depth of sigmoid sinus plate.<sup>3,14,16</sup> The equation derived are as follows,  $D6 = 0.0056 D1 + 0.9056$ ,  $D6 = -0.0257 D2 + 1.0341$ ,  $D6 = -0.0115 D3 + 0.9731$ ,  $D6 = -0.0408 D4 + 1.0681$ ,  $D6 = -0.002 D5 + 0.938$  (Table 3).

In the present study D2 (p value - 0.002) showed statistical significant differences (Table 2). By finding D1, D2, D3 and D5 radiologically, the approximate depth of sigmoid plate (D6) value can be calculated. D4 cannot be used as a reliable landmark as the spine may be absent or not able to trace out in X-ray image.

### Conclusion

The depth of sigmoid sinus plate (D6) can be calculated using the measurements of D1, D2, D3, D4, D5 on lateral view of head & neck X-rays which can be used by Otologist during mastoidectomy to avoid severe bleeding complications from sigmoid sinus. The pre-operative measurement can be taken well in advance using the radiographic images like X-rays and the surgery can be planned accordingly.

### Ethical Committee Approval:

The study was approved by IEC of VMKV Medical College (Reference -VMKVMC/IEC/18/52).

### Conflict of Interest: Nil

### Source of Funding- Self funding

### References

1. Senthil Kumar B, Vijaya Kumar J. Henle's Spine - an Anatomical Landmark for Approaching Various Foramina in the Base of Skull. JKIMSU.2018;7(1):8-15.
2. Peker TV, Pelin C, Turgut HB, Anil A, Sevim A. Various types of suprameatal spines and depressions in the human temporal bone. Eur Arch Oto-Rhino-Laryngol.1998;255:391-5.
3. Aslan A, Mutlu C, Celik O, Govsa F, Ozgur T, Egrilmez M. Surgical implications of anatomical landmarks on the lateral surface of the mastoid

- bone. *Surg Radiol Anat.*2004; 26(4):263-7.
4. Deepthi Sogasu, Thenmozhi M S, Ganesh Lakshmanan. Suprameatal trigone and its relation to the length of the sigmoid sinus. *Drug Invention Today.*2019;12(8):1802-1805.
  5. McMinn RMH. *Last's anatomy: Regional and applied.* Churchill Livingstone. Edinburgh.1998;9:pp.530.
  6. Baily CM. *Surgical anatomy of the skull base.* In: Scott Brown's *Otolaryngology.* Kerr GA. Butterworth Heinemann, London.1997;6(1):pp.1-15.
  7. Peker TV, Pelin C, Turgut HB, Anil A, Sevim A. Various types of suprameatal spines and depressions in the human temporal bone. *Eur Arch Otorhinolaryngol.*1998;255(8): 391-5.
  8. Selman MO. Metric study on depth of the sigmoid sinus plate in relation to suprameatal (Macewen's) triangle. *Iraqi J Med Sci.*2011;9:86-91.
  9. Mohammad O. Selman. Metric study on depth of the sigmoid sinus plate in relation to suprameatal (Macewen's) triangle. *IRAQI J MED SCI.*2011;9(1):86-91
  10. Prabhu LV, Vadgaonkar R, Pai MM, Nayak SR, Krishnamurthy A, Shetty P. Morphometric analysis of the suprameatal region: Clinical significance. *Indian J Otol.*2006;12:6-8.
  11. Subashri A, Thenmozhi MS. Occipital emissary foramina in human adult skull and their clinical implications. *Res J Pharm Technol.*2016;9:716-8.
  12. Viswanatha B, Naseeruddin K. Lateral sinus thrombosis in otology: A review. *Mediterr J Hematol Infect Dis.*2010;2:e2010027.
  13. Milton CM, Cousins VC. A radiological assessment of the usefulness of Macewen's triangle as a surgical landmark. *J Laryngol Otol.*1986;100(11):1225-34.
  14. Turgut HB, Anil A, Peker T, Pelin C, Gulekon IN. Supra-articular, supramastoid and suprameatal crests on the outer surface of the temporal bone and the relation between them. *Surg Radiol Anat.*2003;25(5-6):400-7.
  15. Kronenberg J, Baumgartner W, Migirov L, Dagan T, Hildesheimer M. The suprameatal approach: an alternative surgical approach to cochlear implantation. *Otol Neurotol.* 2004;25(1):41-4.
  16. Luiz AS de Pavia; Marco Segre. Sexing the human skull through the mastoid process. *Rev Hosp Clin Fac Med São Paulo.*2003;58(1):15-20.