

Orofacial Tuberculosis: An Uncommon Manifestation of A Common Disease- A Narrative Review

Padma Charan Patra¹, Priyadarshini Choudhury², Shamimul Hasan³, Shazina Saeed⁴

¹Consultant ENT surgeon, Harish Jagtani (H.J) Hospital, Boulevard Lumumba, Croisement TP, Kinshasa, Democratic republic of Congo 22309, Central Africa, ²Consultant dentist; Oral Medicine and Radiology, Harish Jagtani (H.J) Hospital, Boulevard Lumumba, Croisement TP, Kinshasa, Democratic republic of Congo 22309, Central Africa, ³Professor; Department of Oral Medicine and Radiology, Faculty of Dentistry, Jamia Millia Islamia, New Delhi, ⁴Assistant Professor; Department of Amity Institute of Public Health, Amity University, Noida, Uttar Pradesh

Abstract

Tuberculosis is chronic multisystemic disease caused mostly by Mycobacterium tuberculosis. The disease has its mention in the Vedas and Chakra and Sushruta described the features in the early 600 B.C. TB has a known site predilection for lungs, although, extra pulmonary cases have also been reported. The oral tuberculous lesions are a rare occurrence with atypical signs and symptoms, thus deferring an accurate diagnosis and treatment. A plethora of standard and contemporary diagnostic adjuncts facilitate the rapid and precise diagnosis. Anti-tubercular regimen forms the mainstay of treatment, although several recent drugs are also in clinical trial phase.

This article aims to highlight the etio-pathogenesis, clinical and oral features of tuberculosis, diagnostic tools, and management protocol for tuberculosis. There is also a brief mention on the various policies considered by World health Organization (WHO) to combat this dreaded disorder.

Key Words: diagnostic tools, oral tuberculosis, pulmonary tuberculosis, treatment protocol, tuberculosis.

Introduction

Tuberculosis (TB), a chronic, multisystemic infectious disease is characterized by granuloma formation.¹ Tuberculosis (TB) is considered as a global public health hazard, outnumbering AIDS as the major infectious mortality cause. Early 80's witnessed the decreased TB incidence due to BCG vaccination, anti-TB therapy and improved health care facilities. Resurgence of TB post 1985 occurred due to increased global population, HIV epidemics, deprived sanitary and health care conditions, TB endemic countries immigrants, and

multi drug-resistance to anti TB.^{2,3} Currently, there is a decline in the incidence of TB cases, although, HIV infections and drug resistant strains pose a threat to the absolute abolition of TB.⁴

Robert Koch (1882) discovered the etiologic agent for TB.⁵ National Tuberculosis Association (American Lung Association) was established in 1904.⁶ Albert Calmette and Camille Guerin (1908) made the historic invention of TB vaccine BCG (Bacillus Calmette Guerin). The vaccine was first used on the human population in 1921. The vaccine is now counted in WHO's list of most essential medication for basic health system.⁷

Epidemiology of Tuberculosis

According to the WHO TB Report (2018), TB has affected approximately 10.0 million (range, 9.0–11.1 million) individuals.⁸ The global tuberculosis burden reveals a marked variation among the numerous nations,

Corresponding Author:

Dr. Shazina Saeed,

Assistant Professor; Department of Amity Institute of Public Health, Amity University, Noida, Uttar Pradesh, Tel- +91-9643416889, 0120-4586843

E_mail: ssaeed@amity.edu

ranging from less than five to more than 500 new cases/100 000 population/ year (130 being the average global burden). In 2018, TB associated mortality accounted for 1.2 million (range, 1.1–1.3 million) deaths among HIV-negative individuals (a 27% reduction from 1.7 million in 2000), and 2,51,000 deaths (range 2,23,000–2,81,000) among HIV-positive cases (a 60% reduction from 620 000 in 2000) respectively.⁹ Both sexes in all age groups are affected by TB, Men (aged ≥ 15 years) followed by women and children (aged < 15 years) attributed for 57%, 32%, and 11% of all TB cases respectively. Among all TB cases, 8.6% patients had associated HIV infection (PLHIV).

Most TB cases in 2018 belonged to South-East Asia (44%), Africa (24%) and the Western Pacific (18%), with smaller percentages in the Eastern Mediterranean (8%), the Americas (3%) and Europe (3%). Eight countries accounted for two thirds of the global total: India (27%), China (9%), Indonesia (8%), the Philippines (6%), Pakistan (6%), Nigeria (4%), Bangladesh (4%) and South Africa (3%).¹⁰

India accounted for 35% of global TB deaths among HIV-negative people, and for 30% of the combined total number of TB deaths in HIV-negative and HIV-positive people. In India, notifications increased from 1.2 million in 2013 to 2 million in 2018 (+60%), including a 12% increase of 2,07,000 between 2017 and 2018. (https://www.who.int/tb/publications/global_report/en/)

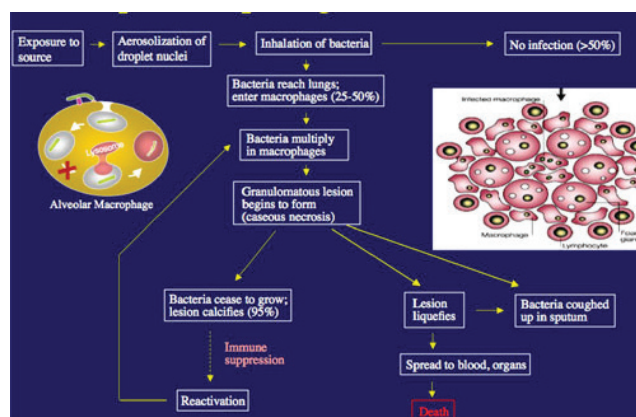
Uttar Pradesh, with 17% of population of the country, is the largest contributor to the TB cases with 20% of the total notifications, accounting to about 4.2 Lakh cases (187 cases/lakh population). (<https://tbcindia.gov.in/WriteReadData/India%20TB%20Report%202019.pdf>)

Etiopathogenesis

The primary causative agent for tuberculosis is *Mycobacterium tuberculosis*.¹¹ Mostly, transmission occurs via the respiratory route due to inhalation of *Mycobacterium tuberculosis* infected air droplets.¹² Intake of unpasteurized cow's milk (infected by *Mycobacterium bovis*) or infection by other atypical mycobacteria may also transmit the disease.¹³

Inhalation of contaminated air droplets causes seeding of *M. tuberculosis* bacilli in the lung alveoli. In immunocompetent individuals, the body defense mechanism (alveolar macrophages) clear this infection. However, in immunocompromised patients, *M. tuberculosis* multiplies inside the macrophages, and gets disseminated to regional lymph nodes, with further infection spread to the lungs, vertebrae, peritoneum, meninges, liver, spleen, and genitourinary tract. Cell-mediated immunity develops at this time and diagnostic tests of tuberculosis become positive. Tuberculosis pathogenesis usually ceases at this stage. The individual is symptom free and is said to have tuberculosis infection.¹⁴

In few cases, tuberculosis infection shows further progression to tuberculosis disease. If a healthy adult acquires *M. tuberculosis* infection, there is 5% to 10% likelihood that TB disease may develop during their life. There is 40% to 50% probability that TB disease may develop within 6 to 9 months in infected but untreated infants and toddlers.¹⁵ Several conditions may predispose to immune-suppression (HIV infection, diabetes mellitus, malnutrition), causing progression from infective phase to disease in adults and children.¹⁶



TB pathogenesis is depicted in Fig.1.

TYPES OF TUBERCULOSIS- PULMONARY AND EXTRA PULMONARY TUBERCULOSIS

TB can be classified as either pulmonary or extra-pulmonary, based on the primary organ system implicated. Pulmonary TB is the most frequently encountered form. Tuberculosis may affect several extrapulmonary sites such as Lymph nodes, peritoneal cavity, genitourinary, nervous system, musculoskeletal system, and hepatosplenic systems.¹⁷

Approximately about 25% of TB lesions are seen in extra pulmonary sites, and head and neck tuberculosis occur in 10- 15% cases. However, primary oral lesions account to less than 1% of primary head and neck lesions. Oral tuberculous lesions may occur either primary or secondary to pulmonary tuberculosis with secondary

lesions being more common.¹⁸ Primary oral tuberculous lesions have an age and site predilection (seen in younger age group, and gingiva being the commonest site), with accompanying regional lymphadenopathy. Tongue is the primary involved site in secondary TB, although palate, lips, buccal mucosa, gingiva and frenum may also be affected.¹⁹

Oral tuberculous lesions usually have diverse manifestations, causing diagnostic dilemmas particularly when oral lesions herald the systemic features. Hence, TB should be considered in the differential diagnosis of suspicious oral pathologies.²⁰

Orofacial TB may involve any structure in and around the oral cavity. Andrade et al. suggested a classification of orofacial TB based on the site involved.²¹

Table 1 Classification of orofacial tuberculosis.

Type I	Lumpy jaw, presenting as an extra oral swelling (No draining sinus tracts intraorally/extra orally).
Type II	History of extraction Non-healing extraction sockets with/without single/multiple draining intraoral/extraoral sinus tracts
Type III	No history of extraction Intraoral / extraoral draining sinus / sinuses in the orofacial region and an osteomyelitis bony lesion
Type IV	Tuberculous lymphadenitis of the orofacial region No manifestations of Type I, II or III
Type V	TB lesions in and around the oral cavity.

Oro-facial TB manifests in various forms: Tuberculous ulcer, Desquamative gingivitis and gingival enlargement, lymph node TB, tuberculoma, tuberculosis of tooth socket, tuberculous osteomyelitis, tuberculous sialadenitis, tuberculosis of maxillary sinus, tuberculous involvement of the Temporomandibular jaw and tuberculosis of skin.^{19,20}

1.Tuberculous Ulcer

Tuberculous ulcer is the most common oral

lesion, appearing as an opalescent vesicle/nodule in its prodromal phase, which eventually rupture forming an ulcer. Tuberculous ulcer typically manifest as an irregular ulcer with undermined edges, mild indurated base covered with a yellowish granular slough.²²

Primary tubercular ulcers are rare, seen primarily in children and young individuals, appearing as shallow/ deep, non-tender ulcers with tender lymph nodes. However, secondary lesions are seen in elderly as painful

ulcers with undermined margins, indurated base, covered with yellowish slough, and non-tender lymph nodes.²³

The most common site for tuberculous ulcers is the tongue (lateral border \leq tip \leq anterior dorsum \leq ventral surface), where it occurs as persistent non-healing ulcer.²⁴ Tuberculosis of the tongue may also manifest as an enlarged tongue (Macroglossia).¹⁹ Traumatic ulcers, aphthous ulcers, syphilitic ulcers and malignant ulcers should be considered in the differential diagnosis of TB ulcers.¹³

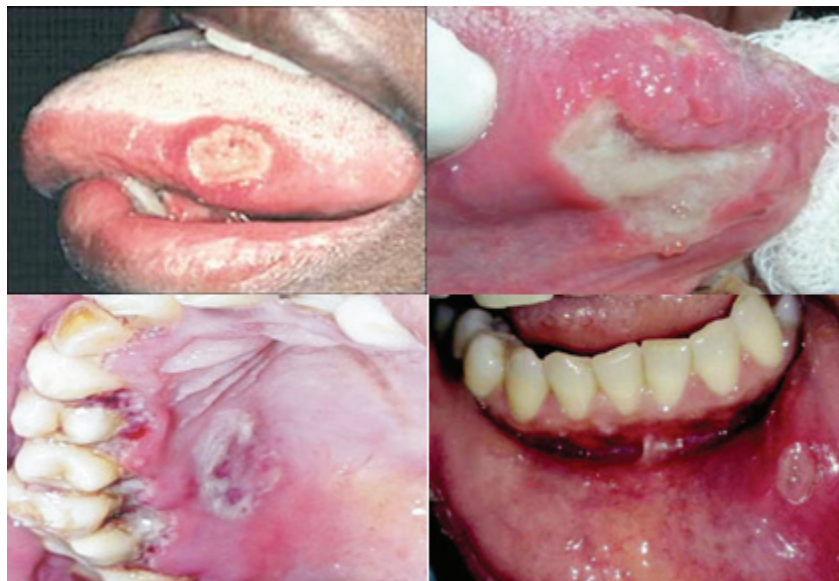

Fig. 2 Various presentations of Tuberculous ulcers.

2. Tuberculous Gingivitis

Gingival tuberculosis may present as solitary proliferating granulation tissues or as mucosal ulcerations/erosions with rare concurrent marginal periodontitis.^{25,26} Desquamative gingivitis may occur in chronic infections, with tuberculosis being the most common chronic infection. Hasan et al. reported an interesting case of oral TB presenting as desquamative gingivitis.¹⁹ There are documented cases of gingival tuberculosis appearing as diffuse gingival enlargement.^{27,28}

Gingival tuberculosis is rare and should be considered in the differential diagnosis of a persistent, recalcitrant, non-healing lesion.^{29,30}

3. TUBERCULOMA

Tuberculous bacteria may reach the periapical tissues of the jawbone via-

A) Salivary acid-fast bacilli may invade the pulp of a deeply decayed tooth causing a periapical tuberculous periapical infection.

B) Blood stream TB dissemination

C) Deep periodontal pocket.³¹

The lesions are painless, rapidly spreading with significant bone involvement.¹⁹

4. TUBERCULOUS INVOLVEMENT OF EXTRACTION SOCKETS OF TEETH

Deferred healing causes replacement of the extraction socket with pinkish-reddish “tuberculous granulation tissue”.³² TB in such cases may result from the treating dentist who was later diagnosed with active pulmonary TB.³³

5. TB LYMPHADENITIS

Lymph node tuberculosis (LNT) is the most frequently occurring form of extra pulmonary TB in low TB prevalence regions. In TB endemic countries, LNT is outnumbered only by TB pleuritis. Mycobacterial cervical lymphadenitis is the most common form of LNT.³⁴ TB lymphadenitis is atypical in its affinity to sex and age, primarily affecting younger age group

females, whereas pulmonary tuberculosis affects older male individuals.³⁵

LNT presents as gradually progressing painless swelling of one/more lymph nodes. Initially, presents as firm, distinct, and mobile LN, later, appearing as matted with inflamed overlying skin. The full-blown cases manifest as softened lymph nodes with abscess and sinus.¹

Jones and Campbell classification³⁶ for LNT -

- Stage 1 - Reactive lymphadenitis - distinct, enlarged, mobile and firm nodes with nonspecific reactive hyperplasia
- Stage 2 - Peri adenitis - Rubbery lymph nodes fixed to underlying tissues
- Stage 3 - Cold abscess formation with softened central region
- Stage 4 - collar-stud abscess
- Stage 5 - Sinus tract formation.

The varied treatment protocol of tuberculous and nontuberculous mycobacterium cervical lymphadenitis warrants the differentiation between the two entities.³⁷

6. TB SALIVARY GLANDS

Salivary gland TB is rare even in TB rampant nations like India. (2.5-10%).³⁸ Primary and systemic TB has a site predilection for Parotid and Submandibular glands, respectively.^{39,40}

According to Van Stubenrauch theory, the infection spreads from the oropharynx along the parotid gland duct (Stenson's duct). According to Bockhorn and Berman postulates, dissemination of infection is through the blood stream and lymphatics, respectively.⁴¹

Tuberculous parotitis is frequently due to Mycobacterium bovis infection and rarely by Atypical mycobacterium.⁴² Parotid TB manifests in the following forms-

1. Acute inflammatory reaction of the gland mimicking sialadenitis, where the gland parenchyma forms multiple small abscess, later resulting in diffuse gland enlargement.⁴³

2. Well circumscribed mass presenting as a progressively enlarging, asymptomatic mass, mimicking parotid neoplasm.⁴⁴

3. Rarely as fistulous tract / abscess in the periauricular region.⁴⁵

7. TUBERCULOUS OSTEOMELITIS

Local and systemic factors (viral infections, blood dyscrasias, chemotherapy and radiotherapy) predisposing to immune suppression usually aid in development of acute and secondary chronic osteomyelitis of the jawbones.⁴⁶

Tuberculous jawbone osteomyelitis accounts only to less than 2% of skeletal tuberculosis.⁴⁷ Maxillary jawbone TB osteomyelitis is rare mainly due to rich vascularity and strut maxillary bone structure.⁴⁸

TB jawbone osteomyelitis typically present as apical osteitis and periodontitis with horizontal bone loss or as an extensive destructive osteolytic lesion, and differentiation with a dental abscess is difficult.⁴⁹

8. TUBERCULOSIS OF TEMPOROMANDIBULAR JAW

TMJ tuberculosis usually occur secondary to a fistulous communication from the middle ear,⁵⁰ and only six cases have been described as primary TB of the TMJ.⁵¹ A recalcitrant, painful preauricular swelling associated with trismus is the most frequently occurring manifestation.⁵² TB of the TMJ must be considered in the differential diagnosis of acute TMJ swelling and bone destruction, especially in TB endemic regions or those at risk of HIV.⁵³

Initially, nocturnal muscle spasm occurs causing soft and elastic joint destruction, eventually causing localized atrophy of the periarticular muscles.⁵⁴ Fibrosis or bony ankylosis, causing erosion of the condyle and glenoid fossa occurs in the advanced cases.

9. LUPUS VULGARIS

Oral lupus vulgaris is an exceptionally rare, however, it is the most common type of cutaneous TB in people with moderate immunity and high tuberculin sensitivity.⁵⁷ In India, the common affected sites are buttocks, thighs, and legs, with rare facial involvement.

Lip mucosa, palate and the gingiva are the common oral sites affected. Disseminated pre-existing skin lupus outbreak, bacterial seeding from contaminated sputum, and hematogenous spread from the primary site may be the proposed pathogenic mechanisms.⁵⁸ Laskaris described 4 cases of lupus vulgaris of the oral cavity.⁵⁹

Lupus vulgaris characteristically presents with a reddish-brown, nodular/plaque-like lesion, and shows an “apple-jelly” color on diascopy test.⁶⁰

10. TB NOSE AND PARANASAL SINUSES

Nasal and paranasal sinuses TB occurs infrequently due to the defensive mechanisms of the nasal mucosal ciliary action (nasal vibrissae) and the nasal secretions bactericidal properties. Maxillary and ethmoid sinuses are most frequently involved.⁶¹

Maxillary sinus TB generally occur secondary to pulmonary tuberculosis.⁶² Nasal blockage/discharge/bleeding (epistaxis) with crusting are the common presenting manifestations.⁶³ Sinonasal TB occur in 3 major forms:(i) mucosal involvement with polyp formation (ii) bony involvement with midfacial defects and fistular tracts (iii) hyperplastic form with granuloma impersonating a malignant lesion.^{64,65}

DIAGNOSTIC AIDS FOR OROFACIAL TUBERCULOSIS

TB diagnosis is usually made by detailed medical history, Physical examination and diagnostic aids like microscopic sputum smear examination, chest radiography and culture methods.

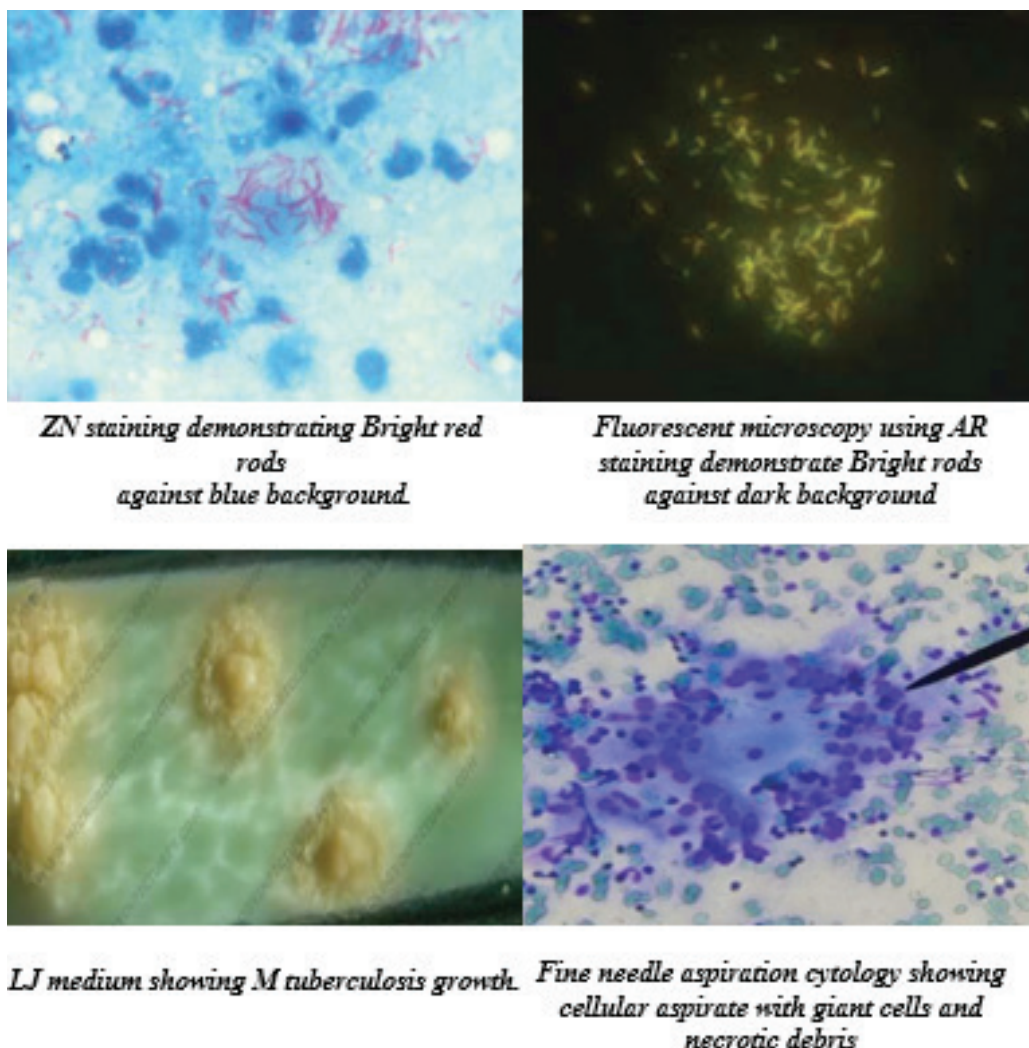


Fig. 3 depicts the various diagnostic aids in orofacial tuberculosis.

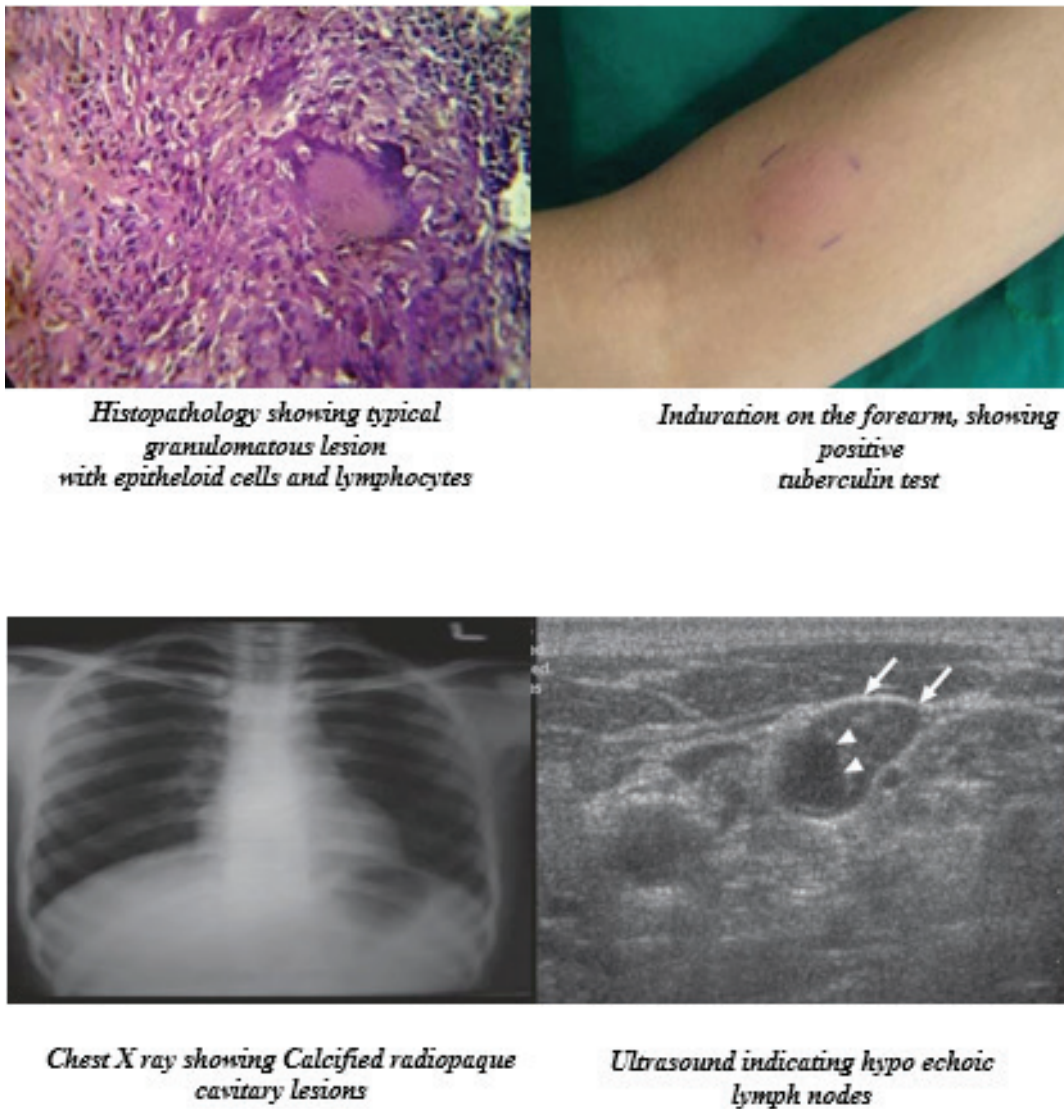


Fig. 3 Diagnostic Aids of Orofacial TB

Prevention of Tuberculosis

Center for disease control and prevention (CDC) has issued certain precautionary measures for health care professional protection.⁶⁶ Elective procedures should be deferred for active/suspected TB cases, and until all the TB investigations are negative.⁶⁷ However, mandatory emergency treatment may be performed with certain precautionary measures-

- a) Appointment at the end of the day
- b) Should be the last treated patient
- c) Universal precautions for infection control-
 - Sterilization and disinfection of the operation

theatres and instruments.

- Use of Rubber dams to prevent aerosol contact (except in patients with evident coughing)
- Proper hand hygiene care
- personal protective equipment (eye shields, HEPA or NIOSH N 95 face masks, head caps, gloves, and surgical gowns)
- Evade direct contact with blood, body fluids and mucous membranes.^{27,68}

BCG VACCINATION

Mycobacterium bovis Bacillus Calmette Guerin (BCG) vaccine is the most common preventive method

to control global tuberculosis. BCG prevents severe disease and reduces death rates from miliary TB among children and meningeal TB in newborns, with variable suboptimal protection against pulmonary tuberculosis in children or adults.⁶⁹ The Modified-Vaccinia-Ankara (MVA) 85A vaccine is an attempt to develop superior novel vaccine.⁷⁰ However, clinical trials and studies have shown that it does not provide enough protection against TB.

TREATMENT PROTOCOL

Anti-tubercular therapy (ATT) regimen varies based on the stage of infection and the individual's risk likelihood. ATT regimen usually entails a drug combination, or a mixture of several drugs in a phasic manner (initial 2-month intensive phase followed by a 4- to 6-month continuation phase).^{71,72}

Directly observed therapy short-term (DOTS) efficiently monitors treatment adherence and completion. With the emergence of MDR-TB, DOTS-plus is a more arduous treatment strategy.⁷³

Table 2 Management of orofacial tuberculosis.1,19,35

DRUGS	MECHANISM OF ACTION	ADVERSE DRUG EFFECTS
FIRST LINE DRUGS		
1.Ethambutol	Inhibits arabinosyl transferase	Optic neuritis, loss of visual acuity
2. Pyrazinamide	Inhibits fatty acid synthetase	Morbilliform rash, Arthralgias, Hyperuricemia
3. Isoniazid	Inhibits fatty acid synthetase	Hepatitis, Peripheral neuropathy Inhibits cytochrome P450 enzymes
4. Rifamycins: Rifampin Rifabutin Rifapentin	Binds to RNA Polymerase and inhibits transcription	Hepatitis, Flu-like symptoms Reddish urination, GIT disturbances
SECOND LINE DRUGS		
1.Cycloserine	Inhibits monomer synthesis	Psychosis, Seizures, Peripheral neuropathy
2.Ethionamine	Inhibits fatty acid synthetase	Hepatitis, Hypothyroidism
3.Aminoglycosides: Streptomycin Capreomycin Kanamycin Amikacin	Binds to 30s ribosomal units and inhibit translation	Ototoxicity, Nephrotoxicity, Neuromuscular blockade

4.Fluoroquinolones: Ciprofloxacin Ofloxacin Gatifloxacin Levofloxacin Moxifloxacin	Inhibits topo-isomerase II (DNA Gyrase), thereby releasing DNA with staggered double stranded breaks	Nausea, Abdominal rashes, Restlessness, Confusion
COMBINATION DRUGS: Rifamate Rifater	Competitive para-amino benzoic acid antagonist Isoniazid+Rifampin Isoniazid+Rifampin+pyrazinamide	GIT disturbances

Persistence and resistance are the primary factors preventing complete TB eradication. The bacilli evoke a chronic inflammatory reaction, causing the bacillary sequestration and preventing drug exposure. This requires extended ATT therapy to eliminate the bacterium, avoiding recurrence.⁷⁴

Drug resistance occurs due to gene mutations, causing a heritable loss of drug susceptibility. Two types of drug resistance are observed in the context of TB.

MDR-TB- Mycobacterium tuberculosis (M. tuberculosis) is resistant to the most efficient first-line ATT.

XDR-TB has additional multi-drug resistance to the most active second-line agents, and fluoroquinolones.⁷⁵

Researches are being conducted to develop novel anti-TB drugs that are economic, have better efficacy, a shorter treatment course, and should be able to treat latent TB, MDR-TB, and XDR-TB.⁷⁶

Table 3 Tabular representation of the recent TB therapeutic development.

Drug category	Mode of action	Brand name	Phase of clinical trial
Diarylquinoline	Inhibits ATP synthesis with disrupted membrane potential	Bedaquiline	III
Nitroimidazoles	Mycolic acid synthesis inhibition. Metabolization releases nitric acid resulting in bacterial cell wall poisoning.	Delamanid PA-824 OPC-67683 TBA 354	III II II Preclinical
Fluroquinolones	Inhibits DNA synthesis	Gatifloxacin, moxifloxacin	III
Ethylenediamine	Inhibits cell wall synthesis	SQ 109	II
Rifamycin	Blocks transcription by inhibitory action on bacterial DNA dependent RNA polymerase.	Rifapentin	II/III

FUTURE PERSPECTIVES AND GOALS TO COMBAT TUBERCULOSIS

World Health Organization (WHO) has adopted Global strategy and targets for tuberculosis prevention, care, and control in 2015 (The End TB Strategy).

https://www.who.int/tb/strategy/End_TB_Strategy.pdf?ua=1

The framework of the post-2015 global tuberculosis strategy is presented in Table 4

Vision	<ul style="list-style-type: none"> • Tuberculosis free world • Zero mortality, ailment, and affliction due to tuberculosis
Goal	<ul style="list-style-type: none"> • End the global tuberculosis epidemic
Milestone for 2025	<ul style="list-style-type: none"> ▪ 75% reduction in tuberculosis deaths ▪ 50% reduction in tuberculosis incidence rates (less than 55 TB cases/100,000 population. TB affected families not to face calamitous charges.
Targets for 2035	<ul style="list-style-type: none"> ▪ 90% reduction in tuberculosis deaths ▪ 90% reduction in tuberculosis incidence rates (less than 10 TB cases/1,00,000 population) TB affected families not to face calamitous charges.

Conclusion

Tuberculosis is a common multisystemic disease, primarily affecting the pulmonary system. Oral TB lesions have bizarre clinical presentation, and the dentists need to be well acquainted with the varied oral features to arrive at an early and accurate diagnosis and treatment. Drug resistance to the various anti-tubercular drugs has posed a serious concern, and several novel ATT are currently in clinical trial phases to combat this complication. WHO has also adopted Global strategy and targets for tuberculosis prevention, care, and control.

Conflict of Interest: The authors declare that they have no conflict of interest.

Source of Funding: Nil

Ethical Clearance: Not Applicable as it is a narrative review.

References

1. Hasan S, Saeed S. Conventional and recent diagnostic aids in tuberculous lymphadenitis: A brief overview. *Asian Journal of Pharmaceutical and Clinical Research* 2017;10(2):78-81.
2. Pai Pang, Duan W, Liu S, Bai S, Ma Y, Li R, et al. Clinical study of tuberculosis in the head and neck region-11 years' experience and a review of the literature. *Emerging Microbes & Infections* 2018;7(1):1-10.
3. Aoun N, El-Hajj G, El Toum S. Oral ulcer: an uncommon site in primary tuberculosis. *Aust Dent J.* 2015;60(1):119-122.
4. Jain P, Jain I. Oral Manifestations of Tuberculosis: Step towards Early Diagnosis. *J Clin Diagn Res.* 2014;8(12):18-21.
5. Gregory, Guptha RB. Incidence of oral manifestations in Tuberculosis. *Journal of Oral Maxillofacial Surgery* 1980;53(2):1334-40.

6. Mandal Ananya MD. History of Tuberculosis. News Medical.net. 2014
7. Luca S, Mihaescu T. History of BCG Vaccine. *Maedica (Buchar)* 2013;8(1):53-58.
8. United Nations General Assembly. Resolution 73/3: Political declaration of the high-level meeting of the General Assembly on the fight against tuberculosis. United Nations; 2018 (https://www.un.org/en/ga/search/view_doc.asp?symbol=A/RES/73/3, accessed 28 June 2019).
9. Treatment Action Group, Stop TB Partnership. Tuberculosis research funding trends 2005–2017. New York: Treatment Action Group; 2018 (<http://www.treatmentactiongroup.org/content/tbrd2018>, accessed 22 July 2019).
10. Target regimen profiles for TB treatment. Geneva: World Health Organization; 2016 ([https:// apps.who.int/iris/bitstream/handle/10665/250044/9789241511339eng.pdf;jsessionid=5F6709C0669BB45006E43153C2B4DF06?sequence=1](https://apps.who.int/iris/bitstream/handle/10665/250044/9789241511339eng.pdf;jsessionid=5F6709C0669BB45006E43153C2B4DF06?sequence=1), accessed 17 July 2019).
11. Cruz A, Starke J. Tuberculosis. In Cherry J, Harrison G, Kaplan S, Steinbach W, Hotez P (ed), Feigin and Cherry's textbook of pediatric infectious diseases. Elsevier Saunders, Philadelphia, PA. 2014;1335-80.
12. Wang WC, Chen JY, Chen YK, Lin LM. Tuberculosis of the head and neck: a review of 20 cases. *Oral Surg Oral Med Oral Pathol Oral Radiol Endod.* 2009;107(3):381-86.
13. Verma S, Mohan RP, Singh U, Agarwal N. Primary oral tuberculosis. *BMJ Case Rep.* 2013;2013: bcr2013010276.
14. Dunn JJ, Starke JR, Revell PA. Laboratory Diagnosis of Mycobacterium tuberculosis Infection and Disease in Children. *Journal of Clinical Microbiology* 2016;54(6):1434-44.
15. Marais B, Gie R, Schaaf H, Hesseling A, Obihara C, Starke J et al. The natural history of childhood intra-thoracic tuberculosis: a critical review of literature from the pre-chemotherapy era. *Int J Tuberc Lung Dis* 2004; 8:392–402.
16. Chiang S, Swanson D, Starke J. New diagnostics for childhood tuberculosis. *Infect Dis Clin North Am* 2015; 29:477–502.
17. Lee JY. Diagnosis and treatment of extrapulmonary tuberculosis. *Tuberc Respir Dis (Seoul)*. 2015;78(2):47-55.
18. Santiago RA, Gueiros LA, Porter SR, Gomes VB, Ferrer I, Leão JC. Prevalence of oral lesions in Brazilian patients with tuberculosis. *Indian J Dent Res* 2013;24:245-48.
19. Hasan S, Khan MA. Tuberculosis - A common disease with uncommon oral features. Report of two cases with a detailed review of literature. *Proceedings of the World Medical Conference* 2011;156-166. ISBN: 978-1-61804-036-7.
20. Bansal R, Jain A, Mittal S. Orofacial tuberculosis: Clinical manifestations, diagnosis, and management. *J Family Med Prim Care* 2015; :335-41.
21. Andrade NN, Mhatre TS. Orofacial Tuberculosis-A 16-year experience with 46 cases. *J Oral Maxillofac Surg* 2012; 70:12-22.
22. S.R.Prabhu and S.k.Sengupta. Bacterial infections due to mycobacteria. Tuberculosis. Oral diseases in the tropics. Oxford university press, 1993: 195-202.
23. Kadar N, Namboodiripad A, Haris M, Divya R. Tuberculous Ulcer of Oral Cavity. *Oral Maxillofac Pathol J* 2017;8(2):105-07.
24. Al-Rikabi AC, Arafah MA. Tuberculosis of the tongue clinically masquerading as a neoplasm: a case report and literature review. *Oman Med J.* 2011;26(4):267-268.
25. Kobayashi T, Sato M, Onoi Y, Ohshiro S, Nishii K, Ishihara T, et al. A case of pulmonary tuberculosis complicated with gingival lesions. *J Kekkaku* 1997; 72(6):411-14.
26. Aneksuk V. Primary tuberculous ulcer of the gingiva: report of 1 case. *J Dent Assoc Thai.* 1988 May-Jun; 38(3):111-15.
27. Jan SM, Khan FY, Bhat MA, Behal R. Primary tuberculous gingival enlargement - A rare clinical entity: Case report and brief review of the literature. *J Indian Soc Periodontol.* 2014;18(5):632-36.
28. Karthikeyan BV, Pradeep AR, Sharma CG. Primary tuberculous gingival enlargement: a rare entity. *J Can Dent Assoc.* 2006;72(7):645-48.
29. Sivapathasundharam B, Gururaj N. Shafer's textbook of Oral Pathology. 5th ed. Bacterial infections of the oral cavity; pp. 438–43.
30. Hasan S, Khan NI, Reddy LB. Leukemic gingival enlargement: Report of a rare case with review of literature. *Int J Appl Basic Med Res.* 2015;5(1):65-

- 67.
31. Brodsky RH, Klatell JS. The tuberculous dental periapical granuloma. *Am J Orthod Oral Surg* 1943; 29:498-502.
 32. Rodrigues G, Carnelio S. Oral tuberculosis: A Review. In: Focus on Tuberculosis Research. In: Smithe Lt, editor. New York; Nova Science Publishers: 2005. p. 172.
 33. Smith WH, Davies D, Mason KD, Onions JP. Intraoral and Pulmonary Tuberculosis following dental treatment. *Lancet* 1982;319:842-44.
 34. Deveci HS, Kule M, Kule ZA, Habesoglu TE. Diagnostic challenges in cervical tuberculous lymphadenitis: A review. *North Clin Istanbul*. 2016;3(2):150-55.
 35. Hasan S, Elangovan E. What's your diagnosis? Multiple jaw masses. *e-Journal of Dentistry* 2013;3(1):343-51.
 36. Jones PG, Campbell PE. Tuberculous lymphadenitis in childhood: The significance of anonymous mycobacteria. *Br J Surg* 1962;50:302-14.
 37. Thakkar K, Ghaisas SM, Singh M. Lymphadenopathy: Differentiation between Tuberculosis and Other Non-Tuberculosis Causes like Follicular Lymphoma. *Front Public Health*. 2016;4:31.
 38. Tauro LF, George C, Kamath A, Swethadri G, Gatty R. Primary Tuberculosis of Submandibular Salivary Gland. *J Global Infect Dis* 2011;3:82-85.
 39. Thakur J, Thakur A, Mohindroo N, Mohindroo S, Sharma D. Bilateral Parotid Tuberculosis. *J Glob Infect Dis* 2011;3:296-9.
 40. Ataman M, Sözeri B, Özçelik T, Gedikoglu G. Tuberculosis of the parotid salivary gland. *Auris Nasus Larynx*. 1992; 19(4):271-73.
 41. Jain A, Meher R, Wadhwa V, Raj A, Tandon S. Parotid tuberculosis: A diagnostic dilemma. *Acta Oto-Laryngologica Case Reports* 2017;2(1):73-76.
 42. Bakhshi GD, Shaikh AS, Borisa AD, Jamadar NM, Singh AG, Vora SH. Primary Tuberculosis of Parotid Gland Mimicking Parotid Tumour. *Bombay Hospital Journal, (Special Issue)*, 2009;14-16.
 43. Sharma SK, Mohan A. Extrapulmonary tuberculosis. *Indian J Med Res*. 2004; 120:316-53.
 44. Shilpa S, Shubha P, Chandorkar S. Parotid gland Tuberculosis: a case report. *Indian J Surg*. 2012; 74:179-180.
 45. Ghorbani GA, Jalalian HR, Akhavan A, et al. Primary tuberculosis abscess of the parotid gland: a case report. *Tanaffos*. 2006;5:65-68.
 46. Baltensperger M, Eyrich G, editors. *Osteomyelitis of the jaws*. Berlin Heidelberg; Springer-Verlag; 2009.
 47. Gadgil RM, Bhoosreddy AR, Upadhyay BR. Osteomyelitis of the mandible leading to pathological fracture in a tuberculosis patient: A case report and review of literature. *Ann Trop Med Public Health* 2012; 5:383-86.
 48. Singh M, Singh S, Jain J, Singh KT. Chronic suppurative osteomyelitis of maxilla mimicking actinomycotic osteomyelitis: A rare case report. *Natl J Maxillofac Surg*. 2010;1(2):153-156.
 49. Chaudhary S, Kalra N, Gomber S. Tuberculous osteomyelitis of the mandible: A case report in a 4-year-old child. *Oral Surg Oral Med Oral Pathol Oral Radiol Endod* 2004; 97:603-06.
 50. Prasad KC, Sreedharan S, Chakravarthy Y, Prasad SC. Tuberculosis in the head and neck experience in India. *J Laryngol Otol*. 2007 Oct; 121(10):979-85.
 51. Katjodkar F, Saxena VS, Maideo A, Sontakke S. Osteomyelitis affecting mandible in tuberculosis patients. *J Clin Exp Dent*. 2012;4(1):72-76.
 52. Helbling CA, Lieger O, Smolka W, Iizuka T, Kuttenger J. Primary tuberculosis of the TMJ: presentation of a case and literature review. *Int J Oral Maxillofac Surg*. 2010; 39(8):834-38.
 53. Patel M, Scott N, Newlands C. Case of tuberculosis of the temporomandibular joint. *British Journal of Oral and Maxillofacial Surgery*. 2012;50(1)1-3.
 54. Soman D, Davies SJ. A suspected case of tuberculosis of the temporomandibular joint. *Br Dent J* 2003; 194:23-24.
 55. Marotti M. Imaging of temporomandibular joint disorders. *Rad 507. Med Sci* 2010; 34:135-48.
 56. Choi JA, Koh SH, Hong SH, Koh YH, Choi JY, Kang HS. Rheumatoid arthritis and tuberculous arthritis: Differentiating MRI features. *AJR Am J Roentgenol* 2009; 193:1347-53.
 57. Mukta V, Jayachandran K. Lung and lupus vulgaris. *Lung India*. 2011;28(2):127-29.
 58. Smoller BR, Horn TD. In *Dermatopathology in systemic disease. Infectious disease and the skin. Mycobacterial infections-Tuberculosis*. New York:

- Oxford: Oxford University Press; 2001. p. 215-57
59. Laskaris GC, Nicolis GD. Lupus vulgaris of the oral mucosa. Report of 4 cases associated with asymptomatic pulmonary tuberculosis. *Dermatologica*. 1981;162(3):183-90.
 60. Dhoat S, Rustin M. The skin in general medicine. *Clin Med* 2009; 9:379-84.
 61. Sethi AD, Sareen DA, Sabharwal AAK, Agarwal AK. Tubercular pansinusitis presenting as nasal polyp. *Indian J Tuberc* 2005; 52:99-101.
 62. Ravi M, Ashu G. Tubercular osteomyelitis of maxilla. *Calicut Med J*. 2005; 3:4.
 63. Kant S, Srivastava R, Verma AK, Singh HP, Singh S, Ranganath TG et al. Maxillary sinus tuberculosis: Various presentations. *Indian J Chest Dis Allied Sci* 2013; 55:175-77.
 64. Jain MR, Chundawat HS, Batra V. Tuberculosis of the maxillary antrum and of the orbit. *Indian J Ophthalmol* 1979; 27:18-20.
 65. Rayapati DK, Prashanth NT, Rangan V, Kalakunta PR. Tuberculosis of the maxillary sinus masquerading as a facial abscess, a unique occurrence. *J Oral Maxillofac Pathol*. 2018;22(Suppl 1):126-30.
 66. Recommended infection-control practices for dentistry. Centers for Disease Control (CDC). *MMWR Morb Mortal Wkly Rep*. 1986;35(15):237-42.
 67. Jensen PA, Lambert LA, Iademarco MF, Ridzon R. Guidelines for preventing the transmission of *Mycobacterium tuberculosis* in health-care facilities, 1994. Centers for Disease Control and Prevention. *MMWR Recomm Rep*. 1994;43(RR-13):1-132.
 68. Kohn WG, Collins AS, Cleveland JL, Harte JA, Eklund KJ, Malwitz DM. Guidelines for Infection Control in Dental Health-Care Settings. *MMWR Morb Mortal Wkly Rep* 2003;52(RR17);1-61.
 69. Rodregues LC, Diwan VK, Wheeler JG. Protective effect of BCG against tuberculous meningitis and miliary tuberculosis: a meta-analysis. *Int J Epidemiology* 1993; 22:1154-58.
 70. Tameris MD, Hatherill M, Landry BS, Scriba TJ, Snowden MA, Lockhart S, et al. Safety and efficacy of MVA85A, a new tuberculosis vaccine, in infants previously vaccinated with BCG: A randomized, placebo-controlled phase 2b trial. *Lancet*. 2013;381(9871):1021-28.
 71. Goldman L, Schafer AI. Tuberculosis: disease overview. In: Goldman L, Schafer AI, editors. *Goldman's Cecil medicine: expert consult premium edition*. 24th ed. St. Louis (MO): Saunders Elsevier; 2011.
 72. Cruz-Knight W, Blake-Gumbs L. Tuberculosis: an overview. *Prim Care* 2013;40(3):743e56.
 73. Fogel N. Tuberculosis: A disease without boundaries. *Tuberculosis* 2015; 95:527-31.
 74. Brauner A, Fridman O, Gefen O, Balaban NQ. Distinguishing between resistance, tolerance, and persistence to antibiotic treatment. *Nat Rev Microbiol*. 2016; 14:320-30.
 75. Koch A, Cox H, Mizrahi V. Drug-resistant tuberculosis: challenges and opportunities for diagnosis and treatment. *Curr Opin Pharmacol*. 2018; 42:7-15.
 76. Olaru ID, Groote-Bidlingmaier FV, Heyckendorf J, Yew WW, Lange C, Chang KC. Novel drugs against tuberculosis: A clinician's perspective. *European Respiratory Journal* 2015;45: 1119-31.