

# Correlation between the Expression of E6 HPV with p53 and p16INK4A at Cervical Adenocarcinoma and Cervical Normal

Gondo Mastutik<sup>1</sup>, Alphaia Rahniayu<sup>2,3</sup>, Nila Kurniasari<sup>2,3</sup>, Anny Setijo Rahaju<sup>2,3</sup>, Rahmi Alia<sup>4</sup>

<sup>1</sup>Associate Professor, Department of Anatomic Pathology, Faculty of Medicine, Universitas Airlangga, Surabaya, Indonesia, <sup>2</sup>Lecture, Department of Anatomic Pathology, Faculty of Medicine, Universitas Airlangga, Surabaya, Indonesia, <sup>3</sup>Researcher, Department of Anatomic Pathology, Dr. Soetomo General Academic Hospital, Surabaya, Indonesia, <sup>4</sup>Researcher, Prof Dr Soekandar Hospital, Mojokerto, Indonesia

## Abstract

**Introduction:** Cervical adenocarcinoma is the second most common type of cervical cancer. The marker to predict the risk of this cancer is still need to be improved. This study aimed to evaluate the correlation between expression of E6 HPV with p53 and p16INK4A in cervical adenocarcinoma and cervical normal. **Methods:** This study was a cross sectional study conducted at the Department of Anatomic Pathology, Dr. Soetomo General Academic Hospital Surabaya Indonesia using 49 paraffin blocks during period January-December 2017. The E6 HPV, p53, and p16INK4A expression were detected by immunohistochemistry staining. **Results:** There were significant differences between the expression of E6 HPV and p16INK4A in cervical adenocarcinoma and cervical normal, but the expression of p53 was no significant difference with  $p=0.060$  ( $P>0.05$ ). There was a positive correlation between the expression of E6 HPV with p53 and p16INK4A ( $p<0.05$ ) in cervical adenocarcinoma and cervical normal, and in cervical adenocarcinoma group, there was a significant correlation between the expression of E6 HPV with p53 ( $p=0.004$ ) and p16INK4A ( $p=0.028$ ), but no correlation was found between p53 with p16INK4A expression ( $p=0,092$ ). **Conclusion:** It suggests that p16INK4A might serve as marker for predicting the risk of developing cervical cancer from the epithelium of cervical normal.

**Keywords:** cervical adenocarcinoma, cervical normal, E6 HPV, p53, p16INK4A

## Introduction

Worldwide, cervical cancer is the third most common cancer ranking after breast and colorectal, with an estimated 530.000 new cases and 275.000 deaths in 2008. It is the fourth most common cause of cancer death ranking below breast, lung, and colorectal cancer. This is estimated that incidence and mortality rate of 15 and 8 per 100.000 respectively<sup>1</sup>. Indonesia has a population of 132.521.684 women and is at great risk for cervical cancer. In 2018, cervical cancer is the second

most common cancer after breast cancer, with 32.469 new cases and 18.279 death<sup>2</sup>. The most common type of cervical cancer is squamous cell carcinoma, which affects ectocervical part, and the second most common type, is cervical adenocarcinoma, which affects the endocervical part, with an incidence of about 15% and the incidence tends to increase<sup>3</sup>.

The cause of cervical cancer is infection of Human Papillomavirus (HPV). The HPV virus infects the cervix through sexual contact, causing cervical squamous cell carcinoma and cervical adenocarcinoma<sup>4-6</sup>. The HPV 16 and 18 cause the 70% of cervical cancer in the world<sup>7-9</sup>, while HPV 6 and 11 cause the 90% of anogenital wart cases<sup>10</sup>. The HPV viral oncogenes, E6 and E7, have shown to be the main contributors to the development of HPV-induced cancers. These oncogenes have the ability to bind host cell regulatory proteins, especially tumor suppressor gene products. The HPV E6 protein

---

### Corresponding Author:

**Gondo Mastutik,**

Associate Professor, Department of Anatomic Pathology, Faculty of Medicine, Universitas Airlangga, Surabaya, Indonesia. St. Prof. Dr. Moestopo No 47, Surabaya Indonesia, 60132. E-mail: gondomastutik@fk.unair.ac.id, gondomastutik@gmail.com

complexes with cellular proteins E6-AP and p53 and facilitates p53 degradation via the ubiquitin-dependent proteolytic system. E6 proteins of both high risk and low risk HPV types bind to p53 *in vitro*, but only E6 proteins of oncogenic HPV types can target p53 for degradation, thus inhibits the stabilization and activation of p53<sup>11</sup>. The HPV oncoprotein E7 is known to bind and inactivate hypophosphorylated retinoblastoma protein (pRB), which eventually leads to upregulation of p16INK4A. P16INK4A is a tumor suppressor protein that inhibits cyclin dependent kinases (CDK)-4 or -6 binding to cyclin D which regulates the G1 cell cycle checkpoints<sup>12</sup>.

Both p53 and p16INK4A in normal cell is almost undetectable by IHC staining. The expression of wild-type p53 (WT) has a very short half-life<sup>13</sup>, therefore it is undetectable by immunohistochemistry (IHC) staining. In HPV infection cases, E6 protein of HPV will degrade p53 protein. p16INK4A protein in normal cells is expressed in very low level and almost undetectable by IHC. Because of the transforming activity of E7 oncogene, p16INK4A is strongly expressed in tumor cells affected by HPV and may be easily detected by IHC<sup>14</sup>. However, the correlation between E6, p53, and p16 do not clear yet. Hence, the objective of this study was to evaluate the correlation between the expression of oncoprotein of E6 HPV with the expression of p53 and p16INK4A in cervical adenocarcinoma and cervical normal.

## Material and Method

This study was a cross sectional study conducted at the Department of Anatomic Pathology, Dr. Soetomo General Academic Hospital, Surabaya, Indonesia during period January-December 2017. The study was approved by Ethics Committee of the Faculty of Medicine, Universitas Airlangga. The specimens of this study were 10 formalin fix paraffin embedded (FFPE) specimens of cervical normal from uterine prolapse cases and 39 FFPE of cervical adenocarcinoma cases. The diagnosis of cervical adenocarcinoma was made by a pathologist. The selection of FFPE samples using purposive random sampling, with inclusion criteria were specimens diagnosed as cervical adenocarcinoma histopathologically and tumor tissue in FFPE still has enough for IHC staining. The Pathologists sort

and adjust between representative slides of cervical adenocarcinoma tissue and paraffin blocks.

E6 HPV was detected by immunohistochemistry (IHC) staining using the HPV16 E6/18 E6 Antibody (C1P5): SC-460 (Santa Cruz Biotechnology). Positive interpretation of the IHC staining was based on nuclear or combined nuclear and cytoplasmic staining. Only cytoplasmic staining was considered as negative<sup>15</sup>. Scoring of the E6 HPV 16/18 was performed using an arbitrary semi quantitative scale. There was no staining that represented negative staining (score 0), 5-25% staining represented mild positive staining (score 1), 25-50% staining represented moderate positive staining (score 2), and >50% represented extensive positive staining (score 3)<sup>16</sup>.

The expression of p53 was detected by IHC staining using monoclonal antibody p53 clone Y5 (Biocare). p53 is regarded as having score 0 if 0-5% of the cells were positive, score 1 if 5-25% of the cells were positive, score 2 if 26-50% were positive, score 3 if 51-75% were positive, and score 4 if >75% of the cells were positive<sup>17</sup>.

p16INK4A expression was detected by IHC staining using the Anti-CDKN2A/p16INK4a Antibody (clone 1E12E10) IHC-plus™ LS-B5261 (LS Bio). Scoring of p16INK4A was negative (score 0) if <1% of the cells were positive, sporadic (score 1) if 1-5% of the cells were positive, focal (score 2) if 5-25% of the cells were positive, and diffuse (score 3) if >25% of the cells were positive<sup>18</sup>.

Statistical analysis to evaluate the differences between the expression of E6 HPV, p53 and p16INK4A at cervical normal tissue and adenocarcinoma tissue was performed using The Kruskal-wallis ( $p < 0.005$ ) test and its correlation was analyzed by Spearman correlation test ( $p < 0.005$ ).

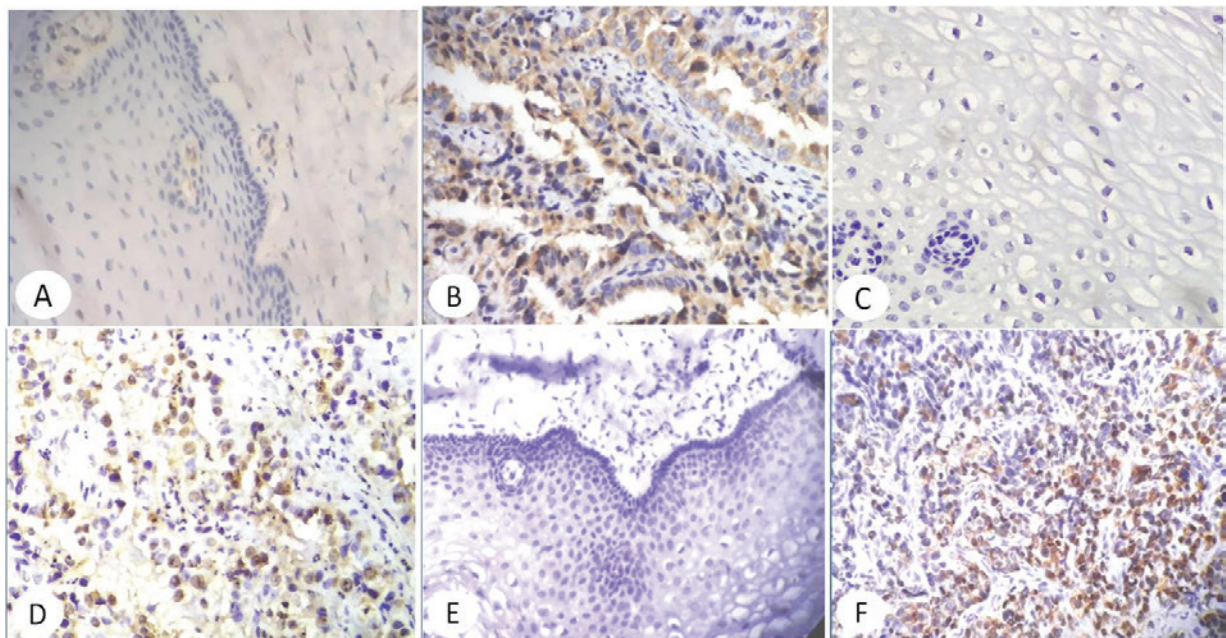
## Result

This study used cervix specimen of women aged 30-81 years with mean + SD of  $51.78 \pm 9.395$ . Cervical normal tissue was found in 10 specimens (20.4%) and cervical adenocarcinoma tissue were in 39 specimens (79.6%) (Table 1).

**Table 1. Ages rank of the patient of cervical normal and cervical adenocarcinoma**

Ages	The number of persons	Percent
30-39	1	2.0
40-49	25	51.0
50-59	13	26.5
60-69	9	18.4
70-79	0	0
80-89	1	2.0
Total	49	99.9

The results showed positivity and negativity for IHC staining of E6 HPV, p53, and p16INK4A expression in cervical normal and adenocarcinoma (Figure 1).



**Figure 1. The immunohistochemistry staining of the E6 HPV, p53, and p16INK4A expression in cervical normal and adenocarcinoma. The expression of the E6 HPV negative staining in cervical normal (A) and positive staining in cervical adenocarcinoma 400 x (B). The expression of p53 negative staining in cervical normal (C) and positive staining in cervical adenocarcinoma 400x (D). The expression of p16INK4A negative staining in cervical normal (E) and positive staining in cervical adenocarcinoma 400x (F).**

The E6 HPV expression in all of the cervical normal were negative, whereas in cervical adenocarcinoma the expression was positive with scores 0, 1, 2, and 3. We found significant difference between the expression of E6 HPV in cervical normal and in cervical adenocarcinoma with  $p=0.001$  ( $P<0.05$ ) (Table 2). Profiles of p53 expression in cervical normal showed that 60% (6/10) had score 0 and 40% (4/10) had scores 1 and 2, whereas in cervical adenocarcinoma the scores varied between 0,

1, 2, 3, and 4, but there was no significant difference with  $p$  value=0.060 ( $P>0.05$ ) (Table 2). Profile of p16INK4A expression in cervical normal showed that 90% (9/10) had score 0 and 10% (1/10) had score 1, whereas in all cervical adenocarcinoma tissues had scores of 1, 2, and 3, and most of the specimens had score 3. Statistical analysis showed that there was a significant difference between p16INK4A expression in adenocarcinoma and cervical normal with  $p<0.0001$  ( $P<0.05$ ) (Table 2).

**Table 2. The profile of E6 HPV, p53, and p16INK4A expression in cervical normal and cervical adenocarcinoma**

Score	Cervical Normal	Cervical Adenocarcinoma	Total	p value
E6 HPV				0.001
0	10 (100%)	14 (35.9%)	24 (49%)	
1	0 (0%)	11 (28.2%)	11 (22.4%)	
2	0 (0%)	11 (28.2%)	11 (22.4%)	
3	0 (0%)	3 (7.7%)	3 (6.1%)	
p53				0.060
0	6 (60%)	12 (30.8%)	18 (36.7%)	
1	3 (30%)	15 (38.5%)	18 (36.7%)	
2	1 (10%)	3 (7.7%)	4 (8.2%)	
3	0 (0%)	4 (10.3%)	4 (8.2%)	
4	0 (0%)	5 (12.8%)	5 (10.2%)	
p16INK4A				< 0.0001
0	9 (90%)	0 (0%)	9 (18.4%)	
1	1 (10%)	1 (2.6%)	2 (4.1%)	
2	0 (0%)	3 (7.7%)	3 (6.1%)	
3	0 (0%)	35 (89.7%)	35 (71.4%)	

There was a significant correlation between the expression of E6 HPV with the expression of p53 and p16INK4A ( $p < 0.05$ ) from all of data both cervical adenocarcinoma and normal. In cervical adenocarcinoma group, there was a significant correlation between the expression of E6 HPV with the expression of p53 and p16INK4A, but in cervical normal, the data could not be analyzed because it was constant (Table 3). The Spearman's coefficient (rs) for expression of E6 HPV and p53 from cervical adenocarcinoma was 0.402 with p value 0.004 ( $p < 0.05$ ). We found significant positive

correlation between the expression of E6 HPV with p53 (Table 3). The rs for expression of E6 HPV with p16INK4A was 0.313 with p value of 0.028 ( $p < 0.05$ ), indicating a positive significant correlation between the expression of E6 HPV with p16INK4A in cervical adenocarcinoma (Table 3). These results indicate that the increase in the expression of E6 HPV is along with increased expression of p16 protein. There was no correlation between p53 expression and p16INK4A with Spearman's coefficient rs 0.244 with p value=0.092 ( $p > 0.05$  (Table 3).

**Table 3.** The Spearman correlation test of the expression of E6 HPV with the expression of p53 and p16INK4A

Correlation		ADC (n=39)	CN (n=10)	Total (n=49)
E6 HPV with p53	The Spearman coefficient	0,352	-	0,402
	P value	0,028		0,004
E6 HPV with p16INK4A	The Spearman coefficient	-0,262	-	0,313
	P value	0,107		0,028
p53 with p16INK4A	The Spearman coefficient	0,034	-0,266	0,244
	P value	0,835	0,458	0,092

Note: ADC= cervical adenocarcinoma, CN= cervical normal

### Discussion

Cervical adenocarcinoma is one of the most frequent epithelial malignancies of the cervix after a squamous cell carcinoma. Screening for this type of adenocarcinoma cancer is more difficult because it is located in the endocervical canal. Therefore the patient is often diagnosed at an advanced stage.

This study used the cervical normal tissue as control group and cervical adenocarcinoma tissue. The expression of E6 HPV in the study was a parameter

for detecting the infection of HPV 16/18. Positive IHC staining showed that it was infected by HPV 16 and or 18 on the tissue. The expression of p53 in this study was a parameter to determine p53 activity in cervical adenocarcinoma tissue and cervical normal as control. p16INK4A expression in this study was a parameter for detecting p16INK4A protein accumulation in the tissues.

This study showed that E6 HPV in cervical normal was negative, while in cervical adenocarcinoma, it was both negative and positive. These suggested that in

cervical normal tissue, there is no expression of E6 HPV 16/18 oncoprotein. This indicated that cervical normal tissue in this study was not infected with HPV 16 and or 18. This study also showed that there was a significant difference in the expression of E6 HPV between cervical normal and adenocarcinoma tissue. This indicates that in adenocarcinoma cervical tissue there is an infection of HPV 16 and or 18. This is in accordance with the results of previous research that the HPV virus infects the cervix in the ectocervical area, causing squamous cell carcinoma and cervical adenocarcinoma<sup>4-6</sup>. The genotype of HPV 16 and 18 cause for 70% of cervical cancer in the world<sup>7-9</sup>, while HPV 6 and 11 account for 90% of the causes of anogenital warts<sup>10</sup>.

HPV E6 protein binds to p53 and stimulated p53 degradation through a binding mechanism called ubiquitin-dependent proteolytic pathway (E6AP) to produce ubiquitination p53 (19,20). Positive results for p53 in IHC staining may indicate accumulation of mutant-type p53 or unbiquitinated form of p53 undergoing degradation, but it still needs further study. Overexpression of p53 suggested accumulation of malfunctioning 53 proteins in the form of mutant p53 or p53 unbiquitination, so that more p53 protein accumulation suggests poor prognosis. Other studies showed that the mutation of p53 gene in cervical adenocarcinoma was more frequent than in squamous cell carcinoma or cervical intraepithelial neoplasia. There was a single nucleotide substitutions in p53 gene detected in 36% cervical adenocarcinoma cases and this mutation was independent from HPV infection status<sup>21</sup>.

Interestingly, p53 was expressed in normal epithelium tissue from uterine prolapse cases. The positive result was found in 40% (4 of 10 tissues). It was also found in cervical adenocarcinoma, and it was positive in 69% (27 of 39 tissues). This suggested that it might be due to the mutant type of p53 and related with the development from cervical normal to cervical cancer.

Inactivation of pRB protein by E7 HPV results in the accumulation of p16INK4A because pRb normally inhibits p16INK4A transcription<sup>18</sup>. p16INK4A is a cellular protein involved in cell cycle regulation and its expression is tightly controlled in normal cells. In normal cells it is expressed very low and often undetectable by

IHC staining p16INK4A is physiologically expressed very low in some cells, especially cells undergoing squamous metaplasia process). In contrast, due to the activity of cell transformation due to the oncogenic E7 HPV High Risk (HR) protein, p16INK4A is expressed very strongly in cervical cells with dysplasia and may easily be detected by IHC. Therefore, p16INK4A may be considered as a surrogate marker for HPV HR oncogene expression<sup>22</sup>. In the epithelium of cervical normal, it was negative for 90% (9/10) specimens and was positive for 10% (1/10) specimens in sporadic appearance. It is also reported that 10% of cervical normal specimens expressed p16INK4A<sup>22</sup>. This study showed that there was a significant difference between p16INK4A protein expression in cervical adenocarcinoma and cervical normal. This finding suggested that it might serve as a marker for predicting the risk of developing cervical cancer in epithelium of cervical normal and the IHC of p16INK4A might be used as supplementary test for cervical specimens.

HPV is an etiological agent of cervical cancer and classified into high-risk and low-risk genotypes according to their association with cancer. The oncogenic proteins are E6 and E7, E6 high risk HPV promote the degradation of p53, while E6 low risk. Expression of the E6 protein from HPV high risk resulted in degradation of p53, whereas E6 from HPV low risk did not<sup>23,24</sup>. The E7 HPV inactivates pRB. There was a correlation between the expression of p16INK4A and pRb in cervical neoplasia<sup>25</sup>. pRB inhibits the transcription of the cyclin-dependent kinase inhibitor gene p16INK4A. Increasing expression of the viral oncogenes in dysplastic cervical cells might thus be reflected by increased expression of p16INK4A<sup>18</sup>. This study showed positive correlation between the expression of E6 HPV 16/18 with the expression of p53 and p16INK4A in cervical adenocarcinoma. Another study also showed an association between p16INK4A and endocervical carcinomas<sup>26</sup>. This indicate that p16INK4A is a specific marker for premalignant and malignant lesions of the squamous and endocervical mucosa<sup>25</sup> and it may be used as an important tool for reducing incorrect diagnosis of adenocarcinoma<sup>26</sup>. However, the expression of E6 HPV 16/18 and p16INK4A between cervical normal and cervical adenocarcinoma were significantly different, while the expression of p53 was not significantly different. It showed that cervical normal tissues were

not infected by HPV 16/18, so that it resulted in no expression of p16INK4A. Therefore, we suggest that pathology centers in Indonesia, where HPV examination cannot be performed, might perform IHC for p16INK4A as a substitute method of examination.

### Conclusion

In conclusion, this study showed positive correlation between the expression of E6 HPV 16/18 with p53 and p16INK4A in cervical normal and cervical adenocarcinoma tissues. We also found significant different expression of E6 HPV 16/18 and p16INK4A between cervical normal and cervical adenocarcinoma tissues. It suggested that p16INK4A might serve as marker for predicting risk of developing cervical cancer in epithelium of cervical normal and the IHC of E6 HPV and p16INK4A may be used as supplementary test for cervical specimens.

**Acknowledgment:** We thank to the Government of the Republic of Indonesia and the Faculty of Medicine, Universitas Airlangga for financial support in this study.

**Funding:** This study was supported by the Ministry of Research Technology and Higher Education of the Republic of Indonesia by the university operational funding.

**Conflict of Interest:** None

**Ethical Permission:** The study was approved by Ethics Committee of the Faculty of Medicine, Universitas Airlangga, using formalin fix paraffin embedded (FFPE) specimens.

### References

1. Arbyn M, Castellsague X, de Sanjose S, Bruni L, Saraiya M, Bray F, et al. Worldwide burden of cervical cancer in 2008. *Ann Oncol.* 2011;22(12):2675-86.
2. Globocan. Cancer Today, Population Fact Sheet, Indonesia Lyon: International Agency for Research on Cancer, World Health Organization; 2018, <http://gco.iarc.fr/today/data/factsheets/populations/360-indonesia-fact-sheets.pdf>,
3. Siriaungkul S, Utaipat U, Suthipintawong C, Tungsinmunkong K, Triratanachat S, Khunamornpong S. HPV genotyping in adenocarcinoma of the uterine cervix in Thailand. *Int J Gynaecol Obstet.* 2013;123(3):226-30.
4. Tjalma WAA, Van Waes TR, Van den Eeden LEM, Bogers JJPM. Role of human papillomavirus in the carcinogenesis of squamous cell carcinoma and adenocarcinoma of the cervix. *Best Pract Res Clin Obstet Gynaecol.* 2005;19(4):469-83.
5. Nam EJ, Kim JW, Hong JW, Jang HS, Lee SY, Jang SY, et al. Expression of the p16(INK4a) and Ki-67 in relation to the grade of cervical intraepithelial neoplasia and high-risk human papillomavirus infection. *J Gynecol Oncol.* 2008;19(3):162-8.
6. Wells M, Ostor AG, Crum CP, Franceschi S, Tommasino M, Nesland JM, et al. Epithelial Tumours. In: Travassoli FA, Devilee P, editors. *World Health Organization Classification of Tumours: Pathology and Genetics of Tumours of the Breast and Female Genital Organ.* Lyon: IARC Press, 2003; p.262
7. World Health Organization. Information Centre on HPV and Cervical Cancer (HPV Information Centre). *Human Papillomavirus and Related Cancers.* 2008.
8. Skiba D, Mehlhorn G, Fasching PA, Beckmann MW, Ackermann S. Prognostic significance of serum antibodies to HPV-16 L1 virus-like particles in patients with invasive cervical cancer. *Anticancer Res.* 2006;26(6C):4921-6.
9. Schiffman M, Castle PE, Jeronimo J, Rodriguez AC, Wacholder S. Human papillomavirus and cervical cancer. *Lancet.* 2007;370(9590):890-907.
10. Hawkins MG, Winder DM, Ball SLR, Vaughan K, Sonnex C, Stanley MA, et al. Detection of specific HPV subtypes responsible for the pathogenesis of condylomata acuminata. *Virology Journal.* 2013;10:137
11. Hietanen S, Lain S, Krausz E, Blattner C, Lane DP. Activation of p53 in cervical carcinoma cells by small molecules. *Proc Natl Acad Sci USA.* 2000;97(15):8501-6.
12. Deschoolmeester V, Van Marck V, Baay M, Weyn C, Vermeulen P, Van Marck E, et al. Detection of HPV and the role of p16(INK4A) overexpression as a surrogate marker for the presence of functional HPV oncoprotein E7 in colorectal cancer. *BMC Cancer.* 2010;10:117
13. Dowell SP, Wilson PO, Derias NW, Lane DP, Hall PA. Clinical utility of the immunocytochemical detection of p53 protein in cytological specimens.

- Cancer research. 1994;54:2914-8.
14. Patil S, Rao RS, Amrutha N, Sanketh DS. Analysis of human papilloma virus in oral squamous cell carcinoma using p16: An immunohistochemical study. *J Int Soc Prev Community Dent.* 2014;4(1):61-6.
  15. Agrawal GP, Joshi PS, Agrawal A. Role of HPV-16 in Pathogenesis of Oral Epithelial Dysplasia and Oral Squamous Cell Carcinoma and Correlation of p16INK4A Expression in HPV-16 Positive Cases: An Immunohistochemical Study. *ISRN Pathol.* 2013;2013:7.
  16. Chaudhary A, Pandya S, Singh M, Singh M, Mehrotra R. Identification of high-risk human papillomavirus-16 and -18 infections by multiplex PCR and their expression in oral submucous fibrosis and oral squamous cell carcinoma. *Head Neck Oncol.* 2013;5:1-10.
  17. Baalbergen A, Ewing-Graham PC, Eijkemans MJ, Helmerhorst TJ. Prognosis of adenocarcinoma of the uterine cervix: p53 expression correlates with higher incidence of mortality. *Int J Cancer.* 2007;121:106-10.
  18. Klaes R, Friedrich T, Spitkovsky D, Ridder R, Rudy W, Petry U, et al. Overexpression of p16INK4A as a specific marker for dysplastic and neoplastic epithelial cells of the cervix uteri *Int J Cancer.* 2001;92(2):276-84.
  19. Crosbie EJ, Einstein MH, Franceschi S, Kitchener HC. Human papillomavirus and cervical cancer. *Lancet.* 2013;382(9895):889-99.
  20. Zaravinos A, Mammas IN, Sourvinos G, Spandidos DA. Molecular detection methods of human papillomavirus (HPV). *Int J Biol Markers.* 2009;24(4):215-22.
  21. Tornesello ML, Annunziata C, Buonaguro L, Losito S, Greggi S, Buonaguro FM. TP53 and PIK3CA gene mutations in adenocarcinoma, squamous cell carcinoma and high-grade intraepithelial neoplasia of the cervix. *J Transl Med.* 2014;12:255.
  22. Izadi-Mood N, Asadi K, Shojaei H, Sarmadi S, Ahmadi SA, Sani S, et al. Potential diagnostic value of P16 expression in premalignant and malignant cervical lesions. *J Res Med Sci.* 2012;17(5):428-33.
  23. Fu L, Van Doorslaer K, Chen Z, Ristriani T, Masson M, Trave' G, et al. Degradation of p53 by Human Alphapapillomavirus E6 Proteins Shows a Stronger Correlation with Phylogeny than Oncogenicity. *PLoS ONE.* 2010;5(9):94-107.
  24. Mesplède T, Gagnon D, Bergeron-Labrecqu F, Azar I, Sénéchal H, Coutlée F, et al. p53 Degradation Activity, Expression, and Subcellular Localization of E6 Proteins from 29 Human Papillomavirus Genotypes. *J Virol.* 2012;86(1):94-107.
  25. Tringler B, Gup CJ, Singh M, Groshong S, Shroyer AL, Heinz DE, et al. Evaluation of p16INK4a and pRb expression in cervical squamous and glandular neoplasia. *Hum Pathol.* 2004;35(6):689-96.
  26. Eleuterio J, Lima TS, Cunha MD, Cavalcante DI, Silva AM. Immunohistochemical Expression of the Tumor Suppressor Protein p16INK4a in Cervical Adenocarcinoma. *Rev Bras Ginecol Obstet.* 2017;39(1):21-5.