

Clinical and Histopathological Study of Diclofenac Sodium-Acetylsalicylic Acid Toxic Effect on Liver of Mice

Rana Abdulla salih

Lect. Department of physiology, biochemistry and pharmacology, College of Veterinary Medicine, University of Baghdad, Iraq

Abstract

Both over-the-counter (OTC) and prescription analgesics-antipyretics like ibuprofen which is nonsteroidal anti-inflammatory drugs (NSAIDs) have effective as well as safe use for long time. Reversible inhibition of cyclooxygenase enzymes is the mode of action of NSAIDs over all. Use of NSAID lead to drug adverse reactions such as cardiovascular and gastrointestinal bleeding also effects of renal. Drug–drug interactions (DDIs) within the NSAID and a concomitant medication cause adverse drug reaction to several cases. DDIs have been reported for example, when commonly used medications as well as some antihypertensive, alcohol, aspirin, antidepressants are coadministered with NSAIDs. Dependent on total drug exposure cause a continuous risk in that the potential for an ADR due to interactions pharmacologic nature. When assessing ADRs potential risk is important to consideration the use of NSAID dose and duration, also the comedication type or class administered. The sub acute toxicity were carried out on thirty mice divided to three equally groups (10 mice in sub group) which were dosed for two weeks daily as follows: group one (control) was given distilled water, the group two was get diclofenac (voltaren) (100mg/kg B.W.) and group three was given diclofenac (voltaren) with aspirin (100mg/kg B.W.) for each together. Clinical signs of toxicity appear as following: abdominal pain, nausea, dizziness, anorexia, ataxia, blueness of the chest area, shortness of breath and Paralysis of the posterior limbs and recumbence, finally the death of mouse. Serum liver enzyme (ALT and AST) were elevated in all groups (diclofenac and diclofenac with aspirin) as compare to control after two weeks. Considering histopathological studies of liver tissue after two weeks of daily treatment, which showed moderated mononuclear cells infiltration in portal area around blood vessels and bile duct for voltaren group and fatty vacuoles in the cytoplasm of hepatic cells, single cells necrosis and severe inflammatory cells infiltration in the capsular area for voltaren with aspirin group. We concluded that diclofenac and diclofenac with aspirin have toxic effect appear by clinical symptoms and damage to liver, furthermore, don't administration of more than one NSAID at same time.

Key word: *Nonsteroidal antiinflammatory drugs, voltaren Na, aspirin, toxicity, liver*

Introduction

NSAIDs (Nonsteroidal anti-inflammatory drugs), are a class of medicine that lower fever and reduce pain, prevents blood clots, with high doses lead to decrease inflammation ⁽¹⁾. The prominent members of this drugs group, aspirin; ibuprofen also naproxen, are mostly available in most countries as over the counter ⁽²⁾.

Adverse effects depend upon the drug specificity, but largely included an high risk of gastrointestinal ulcers with bleeds, also heart attack, as well as disease of kidney ^(3 and 4).

Achieve analgesia by any member of drug groups known as an analgesic or painkiller, pain relief, the work of analgesic drugs with different ways on the peripheral and central nervous systems. Anesthetics different from analgesic, which in some states eliminate, sensation completely, or mainly with temporarily affect. paracetamol one of analgesics (acetaminophen), the nonsteroidal anti-inflammatory drugs (NSAIDs) like salicylates, and opioid drugs, like morphine and oxycodone. Severity and response to other medication was determine that agent to choice when choosing analgesics; (WHO) the World Health Organization, pain ladder, its first step is specifies mild analgesics ⁽⁵⁾.

To choice analgesic is depend on pain type: The less effective analgesics are traditional to pain of neuropathic, also drugs classes which are not considered analgesics normally is often benefit in treatment, like anticonvulsants, also tricyclic antidepressants⁽⁶⁾.

COX inhibit is mechanism of NSAIDs over all, which is an enzyme that change arachidonic acid to prostaglandins, by which pain mediating; fever; and inflammation⁽⁷⁾.

Diclofenac is sold with the brand name (Voltaren) within others, is a NSAID (nonsteroidal anti-inflammatory drug) used for treatment of pain, also inflammatory diseases like gout, take with oral, injection, or skin applied, typically pain released get through half an hour and it lasts for about eight hours, in combination with misoprostol voltaren also available to decline problems of stomach⁽⁸⁾.

The pain of abdominal, nausea, gastrointestinal bleeding, headache, dizziness, and swelling are the common side effect, otherwise serious side effects like stroke, disease of heart, kidney problems, and ulceration of stomach, it is contraindicated in third pregnancy trimester, also idicated through breastfeeding, it is work depend upon decreasing prostaglandin production⁽¹⁾. It lead to cyclooxygenase-1 (COX-1) and cyclooxygenase-2 (COX-2) blocks⁽⁸⁾.

The widely used non-steroidal anti-inflammatory drugs used one is, probably is highly consumed pharmaceutical product mostly in the world. Aspirin, as a cardio-protective drug with an analgesic has a bigger importance recently. Otherwise, due to its adverse effects, the consumption of aspirin is depend on significant morbidity and mortality on many systems organ⁽⁹⁾. Therapeutic use of aspirin for long-term is reported that accompanied to gastrointestinal ulcerations, hepatotoxicity, nephrotoxicity, also renal cell cancer occurrence^(9 and 10).

Acetylsalicylic acid (Aspirin), is a drug of salicylate, synthetic compound has analgesic, antipyretic, antiplatelet also anti-inflammatory properties⁽¹¹⁾. Children have little indications to use aspirin in case Kawasaki disease and Rheumatic fever⁽¹²⁾.

NSAIDs protein binding were decreased when it administered with aspirin, although unknown of this interaction significance clinically, the free NSAID clearance was not changed⁽¹³⁾.

Materials and Methods

Drugs:

1. Voltaren (Diclofenac)

Diclofenac (Voltaren) was tablet, 100mg/kg, Novartis, Switzerland.

2. Aspirin (acetylsalicylic acid)

Aspirin was tablet, 100mg/kg, Bayer, Germany.

Experiments:

Sub acute Toxicity Study:

Animals:

Thirty mice (Albino, Seprige Dawlly BO. CL) were obtained from the Serum and Vaccination Center. The mice 10 weeks old weighing 25-40 g were maintained under uniform environmental conditions. They were housed under controlled temperature 25 °C and exposed to light 12 hours per day before and during study. The mice were placed in cages (Opaque, plastic, measuring 29 x 15 x 12 cm). The mice were supplied with feed (Pellets form, commercial type) *ad libitum*. The animals were adapted for 2 weeks and allocated at the weighted groups.

The mice were split as three equal groups (10 mice to every group) which were to follows:

- 1- First control group treated with distilled water.
- 2- Second treated group by 100mg/kg voltaren orally for 14 days.
- 3- Third group treated with 100mg/kg voltaren with 100mg/kg aspirin orally for 14 days.

Clinical signs

The signs was recorded to 14 days after administration of voltaren and voltaren with aspirin.

Parameter:

Blood serum sample:

Blood sample were collected from rabbits heart directly by (5cc syringe) in a dry, clean and sterile centrifuge tubes, and then left few minutes allowed to be clotted at room temperature before circulation by centrifuge at (3000) rpm for 20 minutes to separate the clear sera which were put in eppendorf tube by micropipette till performing the biochemical analysis (14).

Serum level of Alanine aminotransferase (ALT), Aspartate aminotransferase (AST), and Alkaline phosphatase (AP).

Histopathology:

The mice treated for two weeks, doses found by previous studies as treated dose for mice, which used the 100mg/kg voltaren and 100mg/kg aspirin, liver was used as a sample in histopathological study after two weeks of experiment to each groups. The animal was killed by broken neck with scissor then the liver was obtained and put in plastic container contain formalin solution (10%) and stained with Haematoxylin and Eosin staini

Statistical Analysis

Statistical analysis of data was done by using SAS (Statistical Analysis System - version 9.1). ANOVA One-way and Little significant differences (LSD) test of post hoc were done to determine significant differences within means, significant statistically is consideration to $P < 0.05$ as described by (15).

Results

Subacute Toxicity:

Clinical signs

After administration of voltaren and compination of voltaren and aspirin drugs to the mice have many symptoms of toxicity appear in different degree according to the drug as following: Abdominal pain, Nausea, Dizziness, Anorexia, Ataxia, Blueness of the chest area, shortness of breath, Paralysis of the posterior limbs and recumbence, finally the death of mouse.

Serum Alanine aminotransferase (ALT), Aspartate aminotransferase (AST) and Alkaline phosphatase (AP):

The serum levels of liver enzyme (ALT, AST and ALP) were found to be relatively elevated in the animals received diclofenac and diclofenac with aspirin in all groups (table 1 and chart 1). Serum AST levels through treatment for two weeks showed significantly increase at ($P < 0.05$) between diclofenac group and diclofenac with aspirin as compared to control group. The levels serum of Alanine aminotransferase (ALT) within two weeks of treatment showed significantly increase at ($P < 0.05$) between diclofenac group and control group and no significantly increase on ($P < 0.05$) of diclofenac with aspirin as compared to group of control. The level of serum ALP after two weeks of treatment showed significant decrease at ($P < 0.05$) between diclofenac group and control, otherwise no significantly increase at ($P < 0.05$) of diclofenac with aspirin as compared to control.

Table (1): Serum ALT, AST and ALP levels (IU/L) in mice for each group after (2 weeks) of administration of diclofenac and diclofenac with aspirin.

Test Group	AST	ALT	ALP
Control	14.20±0.73c	13.40±1.07b	74.00±0.70a
Diclofenac	39.20±2.35a	38.00±1.00a	47.80±3.73b
Diclofenac +Asprin	21.00±0.31b	14.60±0.92b	75.40±1.99a
LSD	4.9621	3.0916	7.631

The different letter with means in the same column are different significantly at ($P < 0.05$)

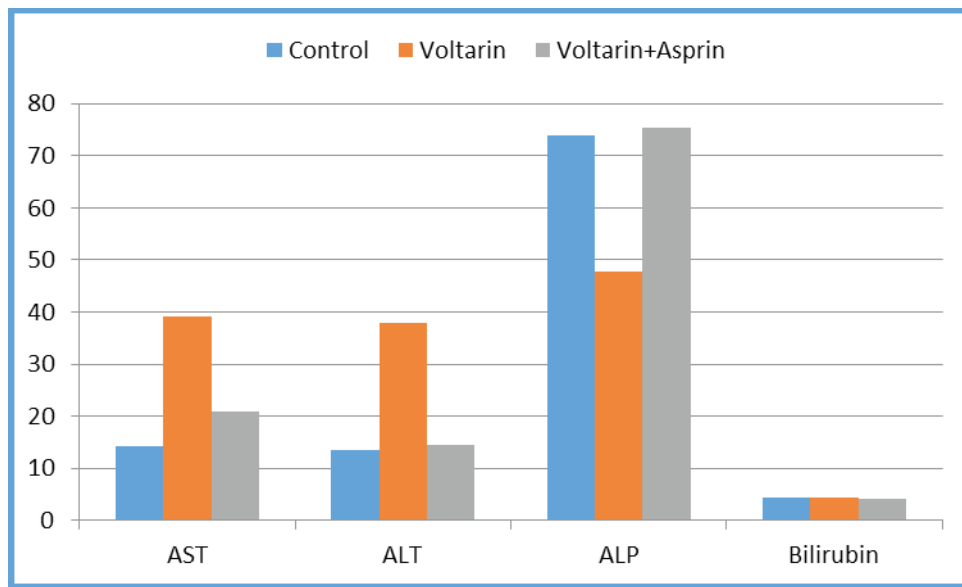


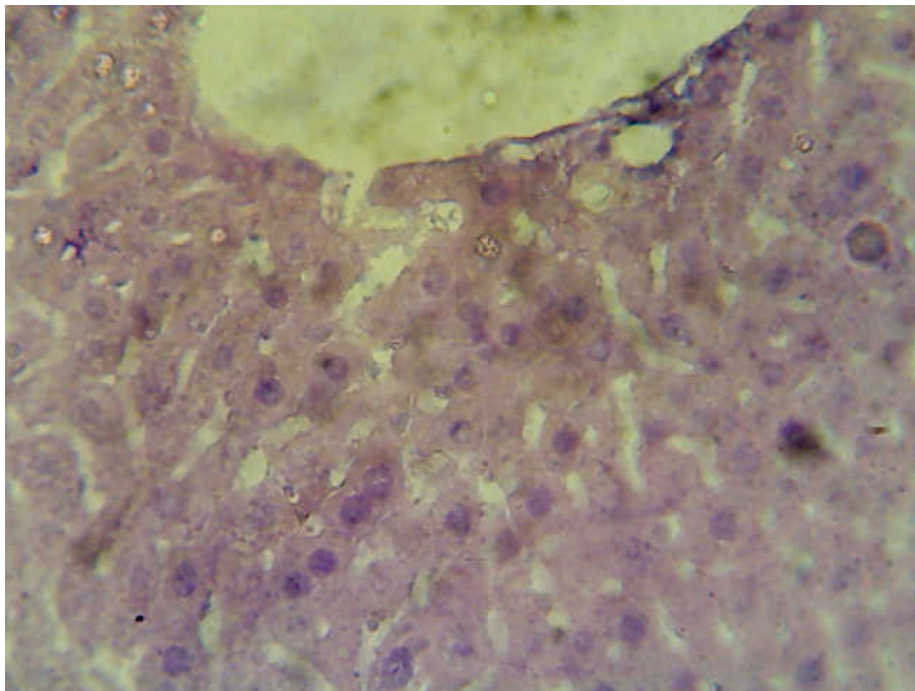
Chart (1): Serum ALT, AST and ALP levels (IU/L) in mice for each group after (2 weeks) of administration of diclofenac and diclofenac with aspirin.

Histopathological results

Results of liver histopathology in all groups after two weeks was obtained as following:

1. Group one (control group):

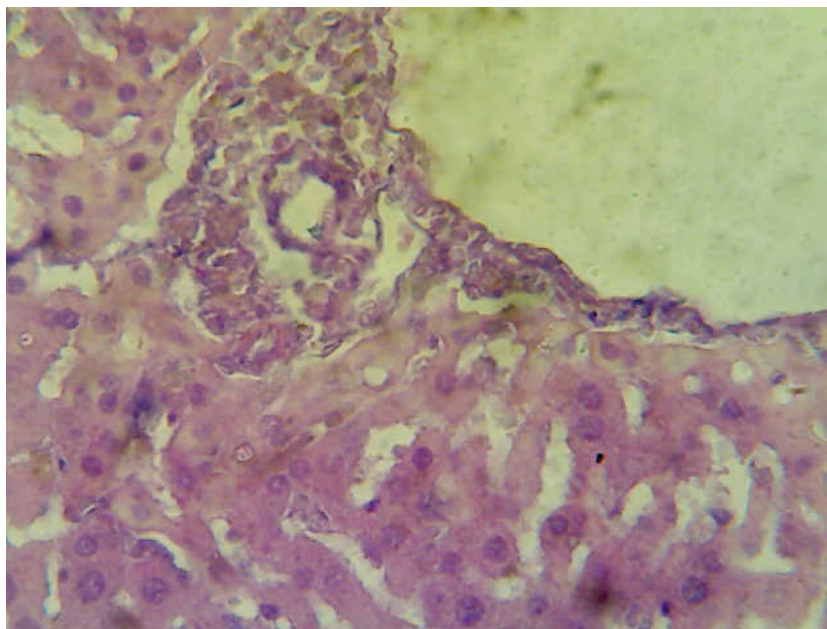
Histopathological sections of the liver tissue in control group after two weeks of the experiment (figures1), with no clear lesions.



(Figure 1): Histopathological section of the liver tissue to mouse treated with distilled water shows: no lesions clear (H & E stain 400X)

2. Group two (diclofenac group):

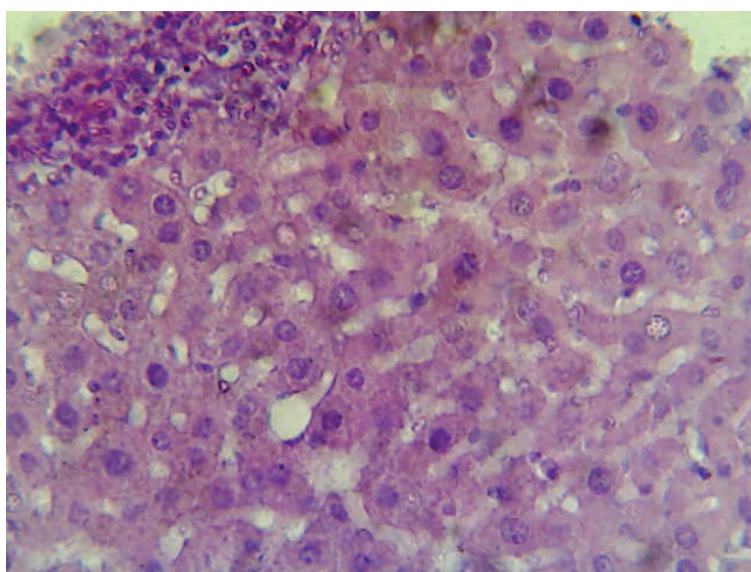
The lesions after two weeks of the experiment in liver tissue (figure 2) were shows moderated mononuclear cells infiltration in portal area around blood vessels and bile duct.



(Figure 2): Histopathological section of the liver tissue of mouse in diclofenac group after 2 weeks of the experiment shows moderated mononuclear cells infiltration in portal area around blood vessels and bile duct (H and E stain 400X).

3. Group three (diclofenac with aspirin group):

The lesions after two weeks of the experiment in liver tissue (figure 3) were shows fatty vacuoles in the cytoplasm of hepatic cells ,single cells necrosis and severe inflammatory cells infiltration in the capsular area.



(Figure 3): Histopathological section of the liver tissue of mouse treated with aspirin and diclofenac shows fatty vacuoles in the cytoplasm of hepatic cells (), single cells necrosis () and severe inflammatory cells infiltration in the capsular area (H & E stain 400X).

Discussion

Diclofenac sodium symptoms include: Diarrhea, drowsiness, headache, dizziness, movement problems, nausea and vomiting (bloody sometimes), numbness and tingling, blurred vision, ringing in the ears, stomach pain (bleeding in stomach and intestines possibility), unsteadiness, rash, urination problems (no urine output to little), edema (body or legs swelling), wheezing^(16 and 17) and this agreement with our present study which found some of this common symptoms.

Hepatotoxicity can be viewed as a result to an adverse interaction between two xenophobic systems within the liver. Drug metabolizing enzymes have evolved as a result of relentless animal-plant warfare for a billion years.

Alternatively, an anti-inflammatory (also immune regulatory) property of IL-10, may be important in drug-induced liver injury⁽¹⁸⁾ as proven by IL-10 knockout mice susceptibility to acetaminophen-induced hepatotoxicity. For that, the relation of cytokine polymorphisms with diclofenac-induced hepatotoxicity proven by in this study probably independent upon immune mechanisms. The liver's ability to produce anti-inflammatory cytokines like IL-10 could, to an extent, be responsible for the low frequency of clinically significant hepatotoxicity⁽¹⁹⁾.

Significant changes to the parameters of biochemical used for toxicity indicators. The levels of ALT, AST and AP in the blood normally are low concentration, those enzymes are considered as biomarkers of hepatic affection and elevated of these enzymes due to a major permeability or cell rupture⁽²⁰⁾.

Drug-induced liver injuries are classified as 'hepatocellular' (cytolytic), with an elevation of alanine transaminase (ALT) predominantly implying hepatocyte necrosis; 'cholestatic', with an elevation of alkaline phosphatase (ALP) predominantly, and 'mixed' pattern based on the ratio of ALT/ALP activity⁽¹⁹⁾.

Liver transaminases (ALT with ALP) are benefit biomarkers of liver injury in a patient has some degree of healthy liver function, since ALP can be increased in other affecting organs diseases, ALT is more considered specific for hepatotoxicity⁽²¹⁾.

Oxidative stress which caused by nitroxide and quinone imine-related redox cycling or putative diclofenac cation radicals and mitochondrial injury (opening of the permeability transition pore and protonophoretic activity) in combination or alone have been appeared in toxicity of diclofenac. For some cases, from a number of experiments demonstrating T cell sensitization and immune mediated liver injury is involved, inferred from unintended re-challenge data⁽²¹⁾.

NSAID (non-steroidal anti-inflammatory drug) like diclofenac, using as antipyretic agent and an analgesic. Liver toxicity with diclofenac is lethal complication when it is not common with NSAIDs⁽²²⁾.

Hepatic degenerative changes by diclofenac which cause cellular damages⁽²³⁾. In this study, treated with diclofenac sodium lead to a significantly increased in ALT, AST, MDA, NO, and Caspase-expression accompanied by significant decline in total protein and albumin, also these results were accompanied by histopathological section and agree with the research⁽²⁴⁾ who reported that, increase of ALT, AST and ALT/AST, also inhibition of albumin and total protein are coinciding with the severity of damages of liver cell because aminotransferases are intracellular enzymes furthermore, rupture of hepatic cell due to circulation escaping of these enzymes ad this agreement with our study results. Damage of liver has been accompanied with induction of the pro-oxidant enzyme iNOS⁽²⁵⁾ producing NO. histopathological results of our study similar to those studied by⁽²⁴⁾ who evoked changes in histological section of liver. Diclofenac sodium appeared to cause hepatic damage by inducing alteration of biomarkers to limit the liver. One of the most sensitive and enthusiastic signs of liver cell damage is the entry of intracellular impulses, for example, transaminases and serum acid neutralizer phosphatase in the cycle⁽²⁶⁾.

⁽²⁷⁾ who found that histopathological study explained seriousness expanded of sores with expanded medication dosage, vacuolation with direct diffuse degeneration, peri-acinar rot with mellow to direct invasion of gateway zones and mononuclear cells in hepatic tissues analyzed of rats administered diclofenac sodium for 14 days at doses of 100 and 150 mg/kg and this agreement with present study.

⁽²¹⁾ was found in histopathologically slides treated by aspirin explained that found a mild to moderate portal inflammation, focal cellular swelling, micro vesicular steatosis with cytolysis and this agreement with present study.

Mitochondrial adenosine triphosphate synthesis is impaired by aspirin, by direct cytotoxic effect or active metabolites leading to permeability elevated of mitochondria, oxygen reactive species overproduction, mitochondrial swelling, nicotinamide adenine dinucleotide phosphate oxidation and protein tiolls which can cause minimal interstitial inflammation with congestion to kidney tissue and hepatic injury. During intake of acute high-dose aspirin have been reported that liver function test abnormalities were reversible; although, during chronic low dose aspirin administration there is no clear data have been reported ⁽²⁸⁾.

Aspirin lower concentration lead to peroxidation which causes impairment in human erythrocytes defense systems antioxidant ⁽²⁹⁾.

⁽¹³⁾ was contraindicated used diclofenac with aspirin because possibility for drug interaction and this was clear from our present study with liver section for administrated diclofenac with aspirin together and this agreement with or hisotopathological result in present study.

Ethical Clearance: The Research Ethical Committee at scientific research by ethical approval of both environmental and health and higher education and scientific research ministries in Iraq

Conflict of Interest:

The authors declare that they have no conflict of interest.

Funding: Self-funding

References

- Mallinson TE. A review of ketorolac as a prehospital analgesic. *Journal of Paramedic Practice*. 2019 Nov 2;11(11):1-6.
- Warden SJ. Prophylactic use of NSAIDs by athletes: a risk/benefit assessment. *The Physician and sportsmedicine*. 2010 Apr 1;38(1):132-8.
- Bally M, Dendukuri N, Rich B, Nadeau L, Helin-Salmivaara A, Garbe E, Brophy JM. Risk of acute myocardial infarction with NSAIDs in real world use: bayesian meta-analysis of individual patient data. *bmj*. 2017 May 9;357.
- Lanas A, Chan FK. Peptic ulcer disease. *The Lancet*. 2017 Aug 5;390(10094):613-24.
- World Health Organization. Cancer pain relief and palliative care: report of a WHO expert committee [meeting held in Geneva from 3 to 10 July 1989]. World Health Organization; 1990.
- Dworkin RH, Backonja M, Rowbotham MC, Allen RR, Argoff CR, Bennett GJ, Bushnell MC, Farrar JT, Galer BS, Haythornthwaite JA, Hewitt DJ. Advances in neuropathic pain: diagnosis, mechanisms, and treatment recommendations. *Archives of neurology*. 2003 Nov 1;60(11):1524-34.
- Moore N, Pollack C, Butkerait P. Adverse drug reactions and drug-drug interactions with over-the-counter NSAIDs. *Therapeutics and clinical risk management*. 2015;11:1061.
- Clatworthy M. *Nephrology: clinical cases uncovered*. John Wiley & Sons; 2010 Mar 8.
- Matzke GR. Nonrenal toxicities of acetaminophen, aspirin, and nonsteroidal anti-inflammatory agents. *American journal of kidney diseases*. 1996 Jul 1;28(1):S63-70.
- McCredie M, Pommer W, McLaughlin JK, Stewart JH, Lindblad P, Mandel JS, Mellempgaard A, Schlehofer B, Niwa S. International renal cell cancer study. II. Analgesics. *International journal of cancer*. 1995 Jan 27;60(3):345-9.
- Awtry EH, Loscalzo J. CHAPTER 60-Aspirin. *Platelets (Second Edition)*. Academic Press: Burlington. 2007:1099-25.
- Hsieh KS, Weng KP, Lin CC, Huang TC, Lee CL, Huang SM. Treatment of acute Kawasaki disease: aspirin's role in the febrile stage revisited. *Pediatrics*. 2004 Dec 1;114(6):e689-93.
- Ribeiro TB, Ribeiro A, de Oliveira Rodrigues L, Harada G, Nobre MR. US Food and Drug Administration anticancer drug approval trends from 2016 to 2018 for lung, colorectal, breast, and prostate cancer. *International Journal of Technology Assessment in Health Care*. 2020;36(1):20-8.
- Lapeyre Mestres M, De Castro AM, Bareille MP, Pozo JG, Requejo AA, Arias LM, Montastruc JL, Carvajal A. Non-steroidal anti-inflammatory drug-related hepatic damage in France and Spain:

analysis from national spontaneous reporting systems. *Fundamental & clinical pharmacology*. 2006 Aug;20(4):391-5.

15. O’Gorman TW. *Applied adaptive statistical methods: tests of significance and confidence intervals*. Society for Industrial and Applied Mathematics; 2004 Jan 1.
16. Aronson JK. Non-steroidal anti-inflammatory drugs (NSAIDs). *Meyler’s Side Effects of Drugs*. 16th ed. Waltham, MA: Elsevier. 2016:236-72.
17. Walls R, Hockberger R, Gausche-Hill M. *Rosen’s emergency medicine-concepts and clinical practice e-book*. Elsevier Health Sciences; 2017 Mar 9.
18. Iyer SS, Cheng G. Role of interleukin 10 transcriptional regulation in inflammation and autoimmune disease. *Critical Reviews™ in Immunology*. 2012;32(1).
19. Aithal GP. Diclofenac-induced liver injury: a paradigm of idiosyncratic drug toxicity.
20. McPherson RA. *Henry’s Clinical Diagnosis and Management by Laboratory Methods: First South Asia Edition_e-Book*. Elsevier India; 2017 Jan 27.
21. Rafeeq A, Najam R, Hussain SJ. Aspirin Associated Liver Toxicity–The Optimal Dose of Aspirin in Liver Insufficiency. *International Journal of Scientific Research in Knowledge*. 2016;4:028-32.
22. Ahmed AY, Gad AM, El-Raouf OMA. Investigations of the Possible Utility of Wheat Germ Oil versus Diclofenac Sodium Induced Liver Toxicity in Rats. 2019;9.
23. Ong CK, Lirk P, Tan CH, Seymour RA. An evidence-based update on nonsteroidal anti-inflammatory drugs. *Clinical medicine & research*. 2007 Mar 1;5(1):19-34.
24. Taha NR, Rabah SO, Shaker SA, Mograby MM. Effect of Moringa oleifera leaves on diclofenac sodium induced hepatic injury in albino rats: ultrastructural and immunohistochemical studies. *Journal of Cytology & Histology*. 2015 Feb 15;6(2):1.
25. Navarro-Antolín J, Redondo-Horcajo M, Zaragoza C, Alvarez-Barrientos A, Fernández AP, León-Gómez E, Rodrigo J, Lamas S. Role of peroxynitrite in endothelial damage mediated by Cyclosporine A. *Free Radical Biology and Medicine*. 2007 Feb 1;42(3):394-403.
26. Lar S, Patel DS, Pandanaboina CS. Hepato-Protective Effects of Blue-Green Alga Spirulina platensis on Diclofenac-Induced Liver Injury in Rats. *Malaysian journal of nutrition*. 2016 Sep 1;22(2).
27. Nasir AS. Biochemical and histological evaluation of diclofenac sodium induced acute hepatotoxicity in rats. *Journal of pharmaceutical sciences and research*. 2018 Apr 1;10(4):733-5.
28. Kesik V, Lenk MK, Kurekci AE, Acikel CH, Akgul EO, Aydin A, Erdem O, Gamsizkan M. Do zinc and selenium prevent the antioxidant, hepatic and renal system impairment caused by aspirin in rats?. *Biological trace element research*. 2008 Jun 1;123(1-3):168-78.
29. Durak I, Karaayvaz M, Cimen MY, Avci A, Çimen ÖB, Büyukkogak S, Oztfirik HS, Ozbek H, Kagmaz M. Aspirin impairs antioxidant system and causes peroxidation in human erythrocytes and guinea pig myocardial tissue. *Human & experimental toxicology*. 2001 Jan;20(1):34-7.