

GATA 3 Reactivity in Adenoid Cystic Carcinoma and Pleomorphic Adenoma of Salivary Glands

Ali Zaki NAJI¹, Ammar Eesa Mahdi²

¹Basic Science Dept. , College of Dentistry, University of Babylon, Assistance professor, F.I.B.M.S pathology, Hilla City, Babylon Province, Iraq, ²Basic Science Dept. , College of Dentistry, University of Babylon, Assistance Lecturer, M.Sc. Histopathology, Hilla City, Babylon Province, Iraq

Abstract

Objectives: The main target is to evaluate clinicopathological distribution and comparison of immunohistochemical (IHC) expression of GATA 3 between adenoid cystic carcinoma (ACC) and pleomorphic adenoma (PA) of salivary glands. **Design and Methods:** This retrospective analysis, open surgical specimens of salivary gland that were done, and consisting of 150 cases that divided into three groups: normal salivary gland tissues (n=50), adenoid cystic carcinoma (n=50), and pleomorphic adenoma (n=50). Clinical data (age, sex, previous diseases), physical examination, and investigations are done for all patients. In addition, these 150 cases of paraffin embedding blocks of salivary tissue were stained by ordinary stain (hematoxylin and eosin staining). Manual IHC staining of GATA 3 was done. **Results:** Age groups are younger for normal salivary gland tissues than PA and ACC. Sex distribution was slightly increased in males in comparison to females in normal salivary gland tissues and PA. GATA 3 staining was showing more positivity in normal salivary gland tissues (43/50 patients) than PA (27/50 patients) and ACC (14/50 patients). This positivity in GATA 3 IHC staining was more in males, regarding 55.8% in normal salivary gland tissues, 50% in ACC, and 51.9% in PA. Age groups 31-40, 40-50, and 61-70 years were showing more positive GATA 3 IHC staining in normal salivary gland tissues, PA, and ACC respectively. There was no significant association between GATA 3 IHC staining with either age groups or sex groups distribution. **Conclusion:** GATA3 IHC is a good marker and can be used for searching salivary gland tumor origin, assisting in diagnosis of salivary gland tumor subtypes but GATA3 IHC staining has no association to specific sex or age groups in salivary gland tumors. Usage of surgical operations for histopathological specimens preparation are better and give good efficiency for IHC markers staining.

Keywords: pleomorphic adenoma, adenoid cystic carcinoma, GATA-binding protein 3, immunohistochemistry.

Introduction

Salivary gland tumors (SGT) are infrequent diseases, 5% from all head and neck neoplasms⁽¹⁾, their incidence is about 1.7/100,000 people in the United States of America (USA)⁽²⁾, and these tumors grow from one of the major or minor salivary glands⁽³⁾.

SGT are characterized by various histopathological pictures between people and in the same patients, and treatment lines are also different between the patients⁽⁴⁾. These tumors show many problems regarding their studying because of difficulty in getting their patients' specimens, little amount of both cell line culture and animal patterns⁽⁵⁾.

Pleomorphic adenoma (PA) and adenoid cystic carcinoma (ACC) are the most common benign and malignant neoplasms of salivary gland respectively^(3,6-7).

ACC is characterized by basaloid cancer and consists of mixed epithelial and myoepithelial tissues with different histopathological pictures⁽³⁾. ACC is the 2nd main cancer (about 10%) in SGT, originates approximately 60% of minor salivary tumors⁽⁸⁻⁹⁾, and its metastasis is mainly (about 50%) to skeleton bone, hepatic and brain tissues⁽¹⁰⁾.

PA is described as a different degree of capsulation and represents around 60% from the total SGT⁽³⁾, with several histopathological configurations that result in

diagnostic troubles^(3,9).

GATA-binding protein 3 (GATA3) is responsible for differentiating of many tissue through their transcriptional function⁽¹¹⁾and existing in wide range of tissues such transitional cell carcinoma, SGT, epidermis of skin, T-lymphocyte, and basal layer of prostate⁽¹²⁾.

SGT should regarded as potential primary location when facing cancer positive for GATA3, but GATA3 cannot discriminate between breast and salivary tumor primary site⁽¹³⁾.

The main aims of this research is evaluate clinico pathological distribution and comparison of immunohistochemical(IHC) expression of GATA 3 between in adenoid cystic carcinoma and pleomorphic adenoma of salivary glands because few studies involved in IHC staining of salivary gland tumors

Methods

This retrospective analysis of open surgical specimens (excisional biopsy) from salivary gland that were done in Al-Hilla Surgical Teaching Hospital, and consisting of 150 cases that divided into three groups: normal salivary gland tissues (n=50), adenoid cystic carcinoma (n=50), and pleomorphic adenoma (n=50).

Clinical data (age, sex, previous diseases), physical examination, and investigations are done for all patients. In addition, the all patients were explained about aim and usage of their surgical specimen for this study.

These 150 cases of paraffin embedding blocks of salivary tissue were stained by ordinary stained (hematoxylin and eosin staining), reexamined by two separated histopathologist to ensure definitive diagnosis of ACC and PA according to WHO Classification of Head and Neck Tumors (4th Edition)⁽¹⁴⁾.

Then, manual IHC staining of GATA 3 to paraffin embedding blocks of salivary tissue were done, according to Bio SB company (Mouse monoclonal antibodies with nuclear staining and BSB2670 catalog no. USA), supported result of this manual procedure by positive (stained with GATA3 score +3) and negative control of breast cancer, which performed with each IHC procedure

Interpretation of GATA 3 IHC staining were depending on nuclear staining of salivary tissue, using intensity grading as weak, moderate, and strong staining, and extension of staining distribution (percentage of nuclear staining of cells) were divided as diffuse ($\geq 50\%$) or focal ($< 50\%$)⁽¹⁵⁾.

The SPSS program (version type 22) was used. Continuous documents were estimated as mean \pm SD and categorical as numbers and percentages. Pearson's chi square (X²) and Fisher's Exact Test were showing the significant difference between categorical groups where P value < 0.05 was significant.

Results

A total 150 patients were included in this study, were divided into 50 patients for each normal salivary gland tissues, PA, and ACC.

Age groups is younger for normal salivary gland tissues (36.36 \pm 8.02) than PA (56.94 \pm 11.73), and ACC (57.42 \pm 14.41). Sex distribution was slightly increase in male in comparison to female in normal salivary gland tissues (male 56% : female 44%) and PA (male 52% : female 48%) while they were the inverse distribution for and ACC (male 48% : female 52%) as illustrated in Table 1.

Table 1 : Clinicopathological basic characteristic in normal and Salivary gland tumors

Characteristics	Sex		Age (years)/ mean \pm SD	Total N.
	Male	Female		
Normal salivary gland tissues	28 (56%)	22 (44%)	36.36 \pm 8.02	50
Pleomorphic adenoma	26 (52%)	24 (48%)	56.94 \pm 11.73	50
Adenoid cystic carcinoma	24 (48%)	26 (52%)	57.42 \pm 14.41	50

GATA 3 immunohistochemical staining was showing more positivity in normal salivary gland tissues (43/50 patients) than PA (27/50 patients) and ACC (14/50 patients). This positivity in GATA 3 IHC staining were more in male sex, regarding 55.8% in normal salivary

gland tissues than ACC 50% and PA 51.9% . There was no association between GATA 3 IHC staining and sex distribution (*P* value =0.638, 0.37, and 0.86)as in table 2.

Table 2 : Compare association of GATA 3 immunohistochemical staining between with normal and Salivary gland tumors according to sex groups.

Parameters	Sex	GATA 3 immunohistochemical staining		P value
		Positive	Negative	
Normal salivary gland tissues	male	24(55.8%)	4(57.1%)	^0.638
	female	19(44.2%)	3(42.9%)	
	Total	43(100%)	7(100%)	
Pleomorphic adenoma	male	14(51.9%)	12(52.2%)	^0.37
	female	13(48.1%)	11(47.8%)	
	Total	27(100%)	23(100%)	
Adenoid cystic carcinoma	male	7(50%)	17(47.2%)	*0.86
	female	7(50%)	19(52.8%)	
	Total	14(100%)	36(100%)	
*Chi-square Test				
^Fisher exact test				

Age group 31-40, 40-50 and 61-70 years were showing more positive GATA 3 IHC staining in normal salivary gland tissues, PA, and ACC respectively. Also, there was insignificant association between GATA 3 IHC staining and age groups distribution (*P* value =0.253, 0.222, and 0.822) as in table 3.

Table 3 : Compare association of GATA 3 immunohistochemical staining between with normal and Salivary gland tumors according to age groups.

Parameters	Age groups	GATA 3 immunohistochemical staining		*P value
		Positive	Negative	
Inflammatory salivary gland tissues	10-20	6(14%)	0(0%)	0.253
	21-30	3(7%)	0(0%)	
	31-40	24(55.8%)	7(100%)	
	41-50	10(23.2%)	0(0%)	
	Total No.	43(100%)	7(100%)	

Cont... Table 3 : Compare association of GATA 3 immunohistochemical staining between with normal and Salivary gland tumors according to age groups.

Pleomorphic adenoma	40-50	14(51.9%)	6(26.1%)	0.222
	51-60	4(14.8%)	8(34.8%)	
	61-70	7(25.9%)	7(30.4%)	
	71-80	2(7.4%)	2(8.7%)	
	Total No.	27(100%)	23(100%)	
Adenoid cystic carcinoma	30-40	2(14.3%)	6(16.7%)	0.822
	41-50	3(21.4%)	8(22.2%)	
	51-60	2(14.3%)	8(22.2%)	
	61-70	6(42.9%)	8(22.2%)	
	71-80	1(7.1%)	4(11.1%)	
	81-90	0(0%)	2(5.6%)	
	Total No.	14(100%)	36(100%)	
*Chi-square Test				

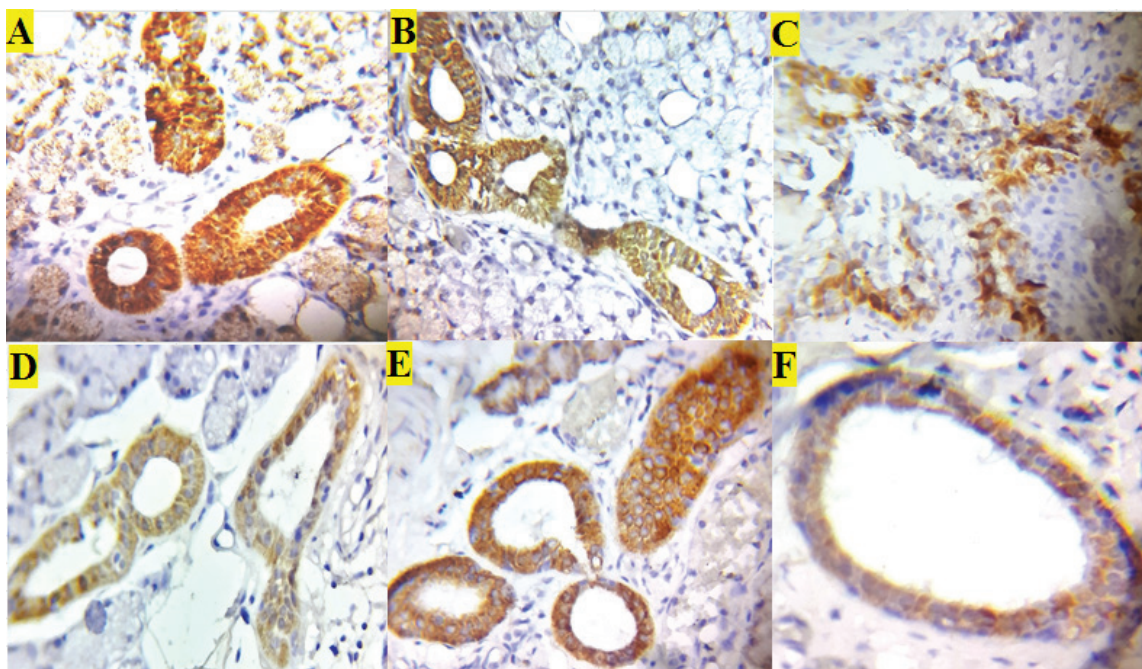


Figure 1: GATA 3 immunohistochemical staining in the Salivary gland tumors : (A)Pleomorphic adenomais showing focal and strong immunoreactivity staining at 40X ;(B) Pleomorphic adenoma is showing focal and moderate immunoreactivity staining at 40X ; (C) Adenoid cystic carcinomais focal and strong immunoreactivity staining at 40X ; (D) Adenoid cystic carcinoma is focal and moderate immunoreactivity staining at 40X; (E-F) Normal salivary gland is showing strong and moderate immunoreactivity staining at 40X respectively.

Discussion

In basis of clinical data, surgical operation for salivary glandsare done for 150 cases, diagnosis arePA, ACC, and normal salivary gland. Sex distributionsare

52% male (N= 78), 48% female (N=72), andage mean is 50.24 years old. Similar study, Fonseca et al⁽¹⁶⁾ include 659 salivary gland tumor that show 54% females, 45% males, and mean age 57.6 years old.

GATA3 IHC staining have helpful for diagnosis, distinguish subtypes of SGT, and although it is related as marker for breast and urothelial cancer but its positivity give hint for searching for SGT⁽¹⁵⁾.

Among 150 patients, 43(86%) patients, 27(54%) patients, and 14(28%) patients are confirmed to be GATA3 positive cases for normal PA, and ACC respectively. Schwartz et al⁽¹⁵⁾ research demonstrate a wide types of salivary tumors, resulting 13/34 (38%) and 9/41 (22%) for PA and ACC respectively. Also, Adkins et al⁽¹⁷⁾ is assessed GATA3 staining in ACC 45% (10/25).

In comparing to studies above, our results, there are a positive GATA3 staining cases in SGT, regarding ACC has 28% positive GATA3 and this result lies between results of two studies above, but PA has high positive GATA3 cases in comparing to Schwartz et al and may related to usage of tissue microarray and this technique has restriction points for tissue evaluation such as its small size, loss of core tumor, and presence of cancer heterogeneity⁽¹⁸⁻²⁰⁾.

The association between sex groups and GATA3 staining is studies. Among PA and normal disease, shows males groups is more positivity than females with equal percentage in ACC. There are no significant difference between sex groups and GATA3 staining.

Also, comparison between age groups with GATA3 staining is involved, resulting age groups 31-40, 40-50, 61-70 years, are more positive for normal, PA, and ACC respectively, with no association between age groups with GATA3 staining for all three diseases.

In conclusion, GATA3 IHC is good marker and can used for searching salivary gland tumor origin, assisting in diagnosis SGT subtypes but GATA3 IHC staining has no association to specific sex or age groups in SGT. Usage of surgical operations for histopathological specimens preparation are better and give good efficiency for IHC markers staining.

Acknowledgement: The all researchers give thanks to medical staffs of Al-Hilla Surgical Teaching Hospital for assistant our work.

Ethical Clearance: the research was accomplished with agreement of national research committee of our

university.

Source of Funding: the research was funded via the two authors above.

Conflict of Interest: The authors state no conflict of interest.

References

1. PM Speight, AW Barrett. "Salivary Gland Tumours." *Oral Diseases*. 2002; 8 (5):229-40.
2. American Cancer Society. "Cancer Facts & Figures 2017." American Cancer Society. 2017.
3. Lester Thompson. "World Health Organization Classification of Tumours: Pathology and Genetics of Head and Neck Tumours." *Ear, Nose, & Throat Journal*. 2006; 85 (2): 74.
4. Julie Carlson, Lisa Licitra, Laura Locati, David Raben, Fredrik Persson, Göran Stenman. "Salivary Gland Cancer: An Update on Present and Emerging Therapies." *American Society of Clinical Oncology Educational Book / ASCO*. American Society of Clinical Oncology. Meeting, 2013; 257-63. doi:10.1200/EdBook_AM.2013.33.257.
5. David J Adelstein, Shlomo A. Koefman, Adel K. El-Naggar, Ehab Y. Hanna. "Biology and Management of Salivary Gland Cancers." *Seminars in Radiation Oncology*. 2012; 22 (3): 245-53. doi:10.1016.2012.03.009.
6. Stenman G, Persson F, Andersson MK. Diagnostic and therapeutic implications of new molecular biomarkers in salivary gland cancers. *Oral Oncol*. 2014 Aug; 50(8):683-90. doi: 10.1016/j.oraloncology.2014.04.008. Epub 2014 May 21. PMID: 24856188.
7. Christopher C. Griffith, Alessandra C. Schmitt, James L. Little, Kelly R. Magliocca. "New Developments in Salivary Gland Pathology: Clinically Useful Ancillary Testing and New Potentially Targetable Molecular Alterations." *Archives of Pathology & Laboratory Medicine*. 2017; 141 (3): 381-95. doi:10.5858/arpa.2016-0259-SA.
8. Patrick J. Bradley. "Adenoid Cystic Carcinoma of the Head and Neck: A Review." *Current Opinion in Otolaryngology & Head and Neck Surgery*. 2004; 12 (2): 127-32.
9. Stenman G. Fusion oncogenes in salivary gland tumors: molecular and clinical consequences. *Head*

- Neck Pathol. 2013 Jul;7 Suppl 1(Suppl 1):S12-9. doi: 10.1007/s12105-013-0462-z. Epub 2013 Jul 3. PMID: 23821214; PMCID: PMC3712096.
10. Cotran, Ramzi, Vinay Kumar, and Tucker Collins. Robbins Pathology Bases of Disease. Sixth Edition. Philadelphia.: W.B. Saunders company. 1999.
 11. Marie-Liesse Asselin-Labat, Kate D Sutherland, Holly Barker, Richard Thomas, Mark Shackleton, Natasha C Forrest, Lynne Hartley, et al. Gata-3 is an essential regulator of mammary-gland morphogenesis and luminal-cell differentiation. *Nat Cell Biol.* 2007 Feb;9(2):201-9. doi: 10.1038/ncb1530. Epub 2006 Dec 24.
 12. Markku Miettinen¹, Peter A McCue, Maarit Sarlomo-Rikala, Janusz Rys, Piotr Czapiewski, Krzysztof Wazny, et al. GATA3: a multispecific but potentially useful marker in surgical pathology: a systematic analysis of 2500 epithelial and nonepithelial tumors. *Am J Surg Pathol.* 2014 Jan;38(1):13-22. doi: 10.1097/PAS.0b013e3182a0218f.
 13. Ellis GL, Auclair PL. Salivary duct carcinoma. AFIP atlas of tumor pathology: tumors of the salivary glands. Washington, D.C. ARP Press. 2008:322–332.
 14. El-Naggar AK, Chan JKC, Grandis JR, Slootweg PJ, editors . WHO Classification of Head and Neck Tumours. 4th Edition, Volume 9 (2017) . ISBN: 9789283224389. Available at IARC Publications.
 15. Schwartz LE, Begum S, Westra WH, Bishop JA. GATA3 immunohistochemical expression in salivary gland neoplasms. *Head Neck Pathol.* 2013 Dec;7(4):311-5. doi: 10.1007/s12105-013-0442-3. Epub 2013 Apr 20. PMID: 23604756; PMCID: PMC3824803.
 16. Fonseca Theresinha C., Eisenberg Ana Lúcia A. Accuracy of intraoperative consultation in lesions of the salivary glands: analysis of 748 cases. *J. Bras. Patol. Med. Lab.* [Internet]. 2015 Feb [cited 2020 Dec 26] ; 51(1): 52-56. Available from: http://www.scielo.br/scielo.php?script=sci_arttext&pid=S1676-24442015000100052&lng=en. <http://dx.doi.org/10.5935/1676-2444.20150011>.
 17. Adkins BD, Geromes A, Zhang LY, Chernock R, Kimmelshue K, Lewis J Jr, et al. SOX10 and GATA3 in Adenoid Cystic Carcinoma and Polymorphous Adenocarcinoma. *Head Neck Pathol.* 2020 Jun;14(2):406-411. doi: 10.1007/s12105-019-01046-w. Epub 2019 Jun 20. PMID: 31222589; PMCID: PMC7235140.
 18. Felipe Paiva Fonseca , Bruno Augusto Benevenuto de Andrade , Ana Lúcia Carrinho Ayrosa Rangel , Ricardo Della Coletta , Márcio Ajudarte Lopes , Oslei Paes de Almeida, et al. Tissue microarray is a reliable method for immunohistochemical analysis of pleomorphic adenoma. *Oral Surg Oral Med Oral Pathol Oral Radiol.* 2014 Jan;117(1):81-8. doi: 10.1016/j.oooo.2013.08.029.
 19. Paiva-Fonseca F, de-Almeida OP, Ayroza-Rangel ALC, Agustin-Vargas P. Tissue microarray construction for salivary gland tumors study. *Med Oral Patol Oral Cir Bucal.* 2013;18(1):e1.
 20. Iwafuchi H, Mori N, Takahashi T, Yatabe Y. Phenotypic composition of salivary gland tumors: an application of principal [corrected] component analysis to tissue microarray data. *Mod Pathol.* 2004;17(7):803–10.