

# Effect of Ammivisnagawater Extract Compared to Proximol (Halfa Bar Extract) in Treatment of induced Renal Lithiasis in a Mature Female Rabbit

Shatha Mahdi Younis<sup>1</sup>, Abdulrazaq N. Khudair<sup>2</sup>, Asia Selman. Abdullah<sup>3</sup>

<sup>1</sup>MSC Student, <sup>2</sup>Professor, Department of Physiology / College of Veterinary Medicine/ University of Basrah,

<sup>3</sup>Assistant Professor, Department of Pharmacology and Toxicology/ College of Pharmacy / University of Basrah

## Abstract

Nowadays people worldwide uses several medicinal plants especially for curing urinary lithiasis. Ammivisnaga is extensively distributed medicinal plant used for management of numerous diseases including urinary lithiasis. *Cymbopogonproximus* or called Halfa-bar suggested for use in medicine for the ejection of ureteric and renal calculi. Ammivisnaga and Halfa-bar found in Asia and several parts of the world. This study aimed at investigating and comparing both Ammivisnaga and Halfa-bar extracts for their antiurolithic activity using a mature female rabbit. Forty-two rabbits randomly divided into four groups. Group A negative control, group B positive control (chemically induced urolithiasis), group C like group B but treated with Ammivisnaga extract 5 ml orally twice daily for 2 weeks and group D like group B but treated with Proximol (Halfa Bar extract) 5 ml twice daily for 2 weeks also. GC-MS analysis of alcoholic extract of Ammivisnaga revealed the detection of main alkaloids Khellin, Visnagin, adulicin and enidimine, with other compounds in lower quantity. The results show that group of induced urinary lithiasis for 14 days and 21 days showed clear body weight loss, higher consumption of drinking water and increased morning urine excretion. In addition to significant increase of blood urea, uric acid, serum creatinine and calcium levels. After 14 days of treatment with Ammivisnaga extract and proximol we noticed reversed body weight loss and overcome low blood urea, serum uric acid, creatinine and calcium. Furthermore, urinary lithiasis groups showed clear crystallization compared to the control urine samples, but after 14 days treatment with Ammivisnaga and proximol extracts, there was nearly clearance of the urine and disappearance of the crystals from the urine. In conclusion, Ammivisnaga and Proximol are safe and good diuretic herbs causes improvement in the body weight, high clearance in urine crystals and amelioration in kidney function compared to untreated group.

**Key words:** Ammivisnaga, Proximol, *Cymbopogonproximus*, urinary lithiasis.

## Introduction

Kidney lithiasis considered as a common disease of high number of people exhibited for many years ago until now. It causes severe pain and several disturbances in

the biochemical and hematological characteristics, that urinary lithiasis may be formed due to the consumption of canned food that contain several chemical materials used as food preservative as well as drinking non-pure water for long period. Although treatment of renal stone nowadays is undertaken by new methods, such as using waves to destroy renal calculi, or by endoscopy or even surgical removal of stone. The mentioned methods have disadvantages like the need to professional people to do it, also, the high cost and possibility of relapse and reformation of the stones in the kidney. In addition to the

---

### Corresponding author

**Dr Asia Selman Abdullah (PhD),**

Assistant professor, Department of Pharmacology and Toxicology, College of Pharmacy, University of Basra, Iraq E-mail : <asiaselman2016@gmail.com>

Phone: 00967- 7719532558

Orcid: 0000-0002-7384-0313

numerous side effect such as kidney tissue destruction resulting in elevation of blood pressure, hemorrhage and ureter obstruction in addition to multiple inflammations which may lead to severe sepsis. The source of stone formation can be calcium oxalate or uric acid stone<sup>1, 2</sup>.

Therapeutic drugs such as diuretics and antibiotics were not sufficiently effective in treatment of renal stones and associated with different side effects<sup>3, 4</sup>. Nowadays people all over the world uses several medicinal plants especially for curing urinary lithiasis, after analysis medicinal plants are found to contain several materials which can affect urolithiasis by different pathways such as relieving spasm, increasing diuresis or decreasing pain<sup>5, 6</sup>.

*Ammivisnaga L.* is a short annual or biennial herb indigenous to the Mediterranean region of North Africa, Asia, and Europe<sup>7</sup>. The plant also distributed throughout North America (North Carolina, Pennsylvania, Oregon, Alabama, California, Florida, and Texas), the Atlantic islands, Argentina, Mexico, and Chile. In Asia, the plant is found in Iraq, Iran, and other western and southern countries. The plant, especially its fruit, has a wide range of applications either in traditional or modern medicine<sup>8</sup>.

Many common drugs developed from this plant, khella. These drugs includes cromolyn, amiodarone and nifedipine. Khellin, which isolated from khella, used for the treatment of asthma and angina pectoris. Furthermore, it is used with the phototherapy for vitiligo, alopecia areata and psoriasis.

Khellin can inhibit citrate metabolism. It was reported that urinary citrate is important to reduce the recurrences of calcium oxalate urinary stones<sup>7</sup>. The most popular type of urinary stone is calcium oxalate stones, constitute about 80% of total stone types and citrate is a known inhibitor of calcium oxalate crystallization<sup>9</sup>.

*Cymbopogon proximus* or called Halfa-bar is an aromatic grass extensively growing in Upper Egypt, the genus *Cymbopogon*, from Gramineae family. It was suggested for use in medicine as diuretic, abdominal or renal antispasmodic, act by relaxation of the fibers of

smooth muscle without eliminating propulsive move of the tissue; therefore, it is used for the ejection of ureteric and renal calculi<sup>10</sup>.

This study aimed at investigating and comparing both *Ammivisnaga* and *Halfa-bar* extracts for their antiurolithic activity using a mature female rabbit. *Ammivisnaga* and *Halfa-bar* found in Asia and several parts of the world.

## Material and Methods

Current study done at the department of Physiology, Pharmacology and biochemistry of College of veterinary medicine, University of Basrah; in the period from October 2019 to March 2020. Twenty-four healthy adult female rabbits weighing 1-1.5 kg, obtained from local animal market at Basrah city, and housed in the animal house of the college of Veterinary medicine / University of Basrah. The rabbits housed separately in cages under controlled room temperature around 25°C and 12 hours dark-light cycle. The animals have free access to food and water (ad libitum) throughout the study. However, the food and water were restricted 24 hours before urine collection. Cages of the animal were cleaned regularly, and animal kept for seven days for adaptation prior to the start of the experiment.

### Preparation of AmmiVisnaga plant extract:

Seeds of *Ammivisnaga* plant bought from the Basrah market. The seeds air-dried in 40°C oven, after that dried seeds were crushed. About 180g of seeds placed in 500 ml of distilled hot water and soaked for 3 days in pure water with occasional shaking at room temperature, the filtration was done using clean muslin cloth and through Whatman qualitative grade 1 filter paper. The procedure repeated twice, and all the filtrate combined and called as crude extract. This extract used for administration to animals.

This crude extract of *Ammivisnaga* screened for the presence of different phytochemical materials by drying to harvest dried powder. After that, the dried powder soaked in 70% ethanol as a solvent and a rotary vacuum evaporator under reduced pressure used to get alcoholic

extract and to eliminate the solvent. This extract screened for the presence of different phytochemical materials such as alkaloids, saponin, coumarins, khillin, visnagin and flavonoid by using GC mass.

### **Experimental induction of urolithiasis**

Calcium oxalate urolithiasis was induced in the kidney of female rabbits in both untreated and treated groups using 2 ml of (0.75%) ethylene glycol orally for each animal daily for 21 days and 2 ml of 1 % ammonium chloride orally for the first 5 days only and 2 ml of disodium oxalate orally for 21 days. Control group was drenched 2 ml of normal saline for 21 days.

Ethylene glycol administration is a common method for the induction of experimental urolithiasis, it has been used alone or in combination with other drugs such as ammonium chloride for the study of kidney calcium oxalate crystals deposition. To achieve uniformly high rate of kidney crystal deposition, ammonium chloride has been drenched in the first 5 days of the experiment as it causes acidification of the urine and hence enhances calcium oxalate crystallization.

### **Animal's treatment**

The rabbits were divided randomly into four groups (6 rabbits each), the first group (Group A) drenched only 2 ml of normal saline daily orally throughout the experiment period (21 days) and considered as negative control group. The second group (group B) was drenched ethylene glycol (0.75%) twice daily and disodium oxalate (350 mg in 100 ml distilled water) 2ml daily orally for 21 days. In the last week, the dose increased to 3 ml twice daily and considered as a positive control. The third group (group C) was drenched like group B but treated with Ammi visnaga extract 5 ml orally twice daily for 2 weeks. The fourth group (group D) drenched like group B but treated with Proxamol (Halfa Bar extract) 5 ml twice daily for 2 weeks also.

### **Sample collection for analysis:**

Urine samples collected at the morning from all groups and analyzed by urine strips method to know the

changes in biochemical constituents.

Blood samples were collected from all groups by cardiac puncture to estimate renal function test including blood urea, serum creatinine, serum uric acid and serum calcium.

### **Statistical Analysis**

Result gained in this experiment were estimated as a mean  $\pm$  standard error of the mean (SEM). The significant variance between groups were measured by ANOVA using the SPSS followed by post-hoc test. The comparison between groups was estimated by least significant difference (LSD) test ( $P \leq 0.05$ ).

### **Findings**

The samples collected and investigated after the chemical induction of urinary lithiasis and after two weeks treatment of rabbits with Ammi visnaga and proxamol extracts.

The group of induced urinary lithiasis for 14 days and 21 days showed clear body weight loss, higher consumption of drinking water and increased morning urine excretion. In addition to significant increase of blood urea, uric acid, serum creatinine and calcium levels (table 1)

After 14 days of treatment with Ammi visnaga extract and proxamol we noticed reversed body weight loss and overcome low blood urea, serum uric acid, creatinine and calcium as shown in (table 1).

After three weeks of induction, urinary lithiasis groups showed bad effects in urine examination significantly different from control group, these effects includes urinary crystals, increased bilirubin, increased urine total protein loss, decreased urinary acidity, increased leucocyte contents, increased nitrite, increased urobilinogen, increased blood content as well as significant increase in urine glucose and ketone bodies. The only parameter, which is not significantly affected, is the urine specific gravity, as shown in (table 2).

**Table 1: Effect of AmmiVisnaga and Proximolextractson kidney function of chemically induced lithogenic female rabbits (mean ± SD).**

Parameters (mg/dl)	Treatments					LSD
	Control	14 days lithogenic treatment	21 days lithogenic treatment	14 days AmmiVisnaga	14 days proximol	
Blood urea	45.3 ± 1.2 A	49.2 ± 1.3 A	246.0 ± 3.4 B	68.6 ± 2.5 C	127.4 ± 4.2 D	7.5
S. Creatinine	0.59 ± 0.16 A	0.69 ± 0.18 A	4.55± 1.12 C	1.18 ± 0.67 B	2.12 ± 0.71 D	0.15
S. Uric acid	0.28 ± 0.12 A	0.30±0.13 A	0.60 ± 0.15 B	0.24 ± 0.10 A	0.38 ± 0.11 A	0.10
S. Calcium	10.03 ± 1.2 A	11.80 ± 1.4 A	14.18 ± 1.6 B	10.30 ± 1.8 AC	11.91 ± 1.85 A	2.1

Means bearing different capital letters differ significantly at 5 % level (P< 0.05)

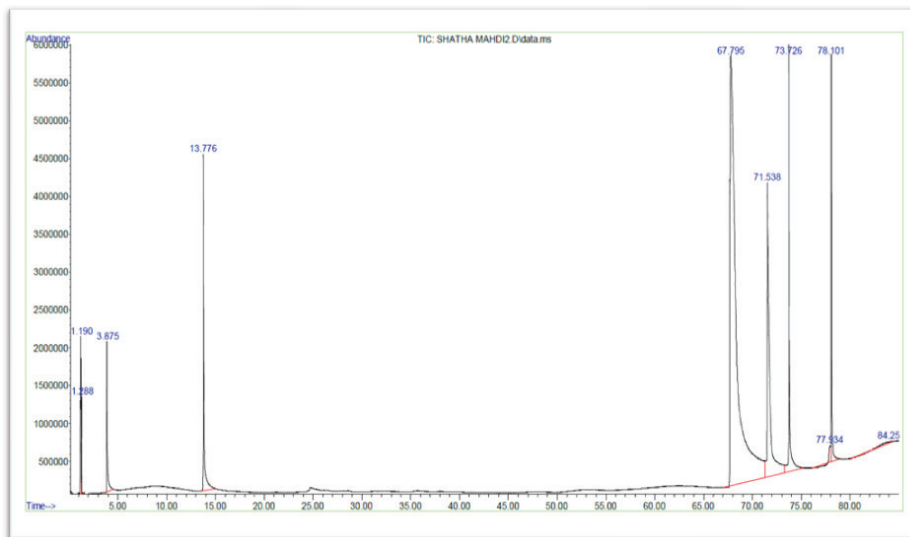
**Table 2: Effect of AmmiVisnaga and Proximolextractson the urine examination of chemically induced lithogenic mature female rabbits (Mean ± SD)**

Parameters	Treatments					LSD
	Control	14 days lithogenic treatment	21 days lithogenic treatments	14 days AmmiVisnaga	14 days proximol	
Bilirubin mg/dl	0.03 ± 0.01 A	15 ± 2 B	17 ± 2 C	0.1 ± 0.01 D	0.2 ± 0.02 E	2
Leucocytes	0.0 ± 0.0 A	10 ± 3 B	11 ± 2 B	2.1 ± 0.5 C	1 ± 0.0 A	3
Nitrite	0.0 ± 0.0 A	3.4 ± 1.4 B	4.1 ± 1.3 B	0.0 ± 0.0 C	0.0 ± 0.0 C	3
Urobilinogen mg/dl	0.8 ± 0.1 A	0.9 ± 0.2 A	16 ± 1.0 B	3 ± 1.1 C	0.5 ± 0.1 C	3
Protein mg/dl	0.423 ± 0.10 A	1.5 ± 0.5 B	3 ± 1.2 C	0.0 ± 0.0 A	0.2 ± 0.02 D	1
pH	5.01 ± 1.1 A	5.5 ± 1.2 A	9.5 ± 1.4 B	5 ± 1.6 A	6 ± 1.5 A	2
Blood mg/dl	0.01 ± 0.0 A	80 ± 5 B	200 ± 6 C	0.0 ± 0.0 A	0.0 ± 0.0 A	10
Glucose mg/dl	0.3 ± 0.01 A	5 ± 0.2 B	7 ± 0.4 C	0.2 ± 0.02 A	0.2 ± 0.02 A	4
Specific gravity	1.01 ± 0.01 A	1.03 ± 0.02 A	1.1 ± 0.02 A	1 ± 0.03 A	1 ± 0.03 A	0.01
Ketone mg/dl	0.0 ± 0.0 A	0.5 ± 0.05 B	0.5 ± 0.05 B	1.0 ± 0.0 A	0.0 ± 0.0 C	0.01

Means bearing different capital letters differ significantly at 5 % level (P<0.05)

### GC-MS analysis of AmmiVisnaga extract:

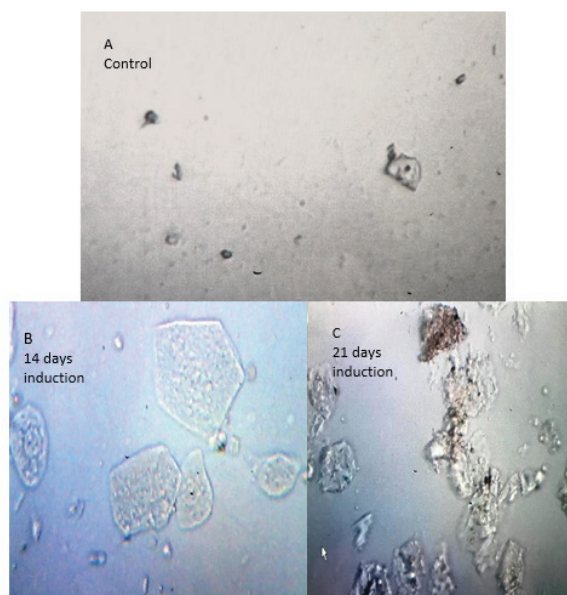
GC-MS analysis of alcoholic extract of AmmiVisnaga revealed the detection of the main four components Khellin, Visnagin, adulicin and enidimine, appeared as high peaks in the figure, while the lower peaks represented other less contents of other compounds, as illustrated in figure 1.



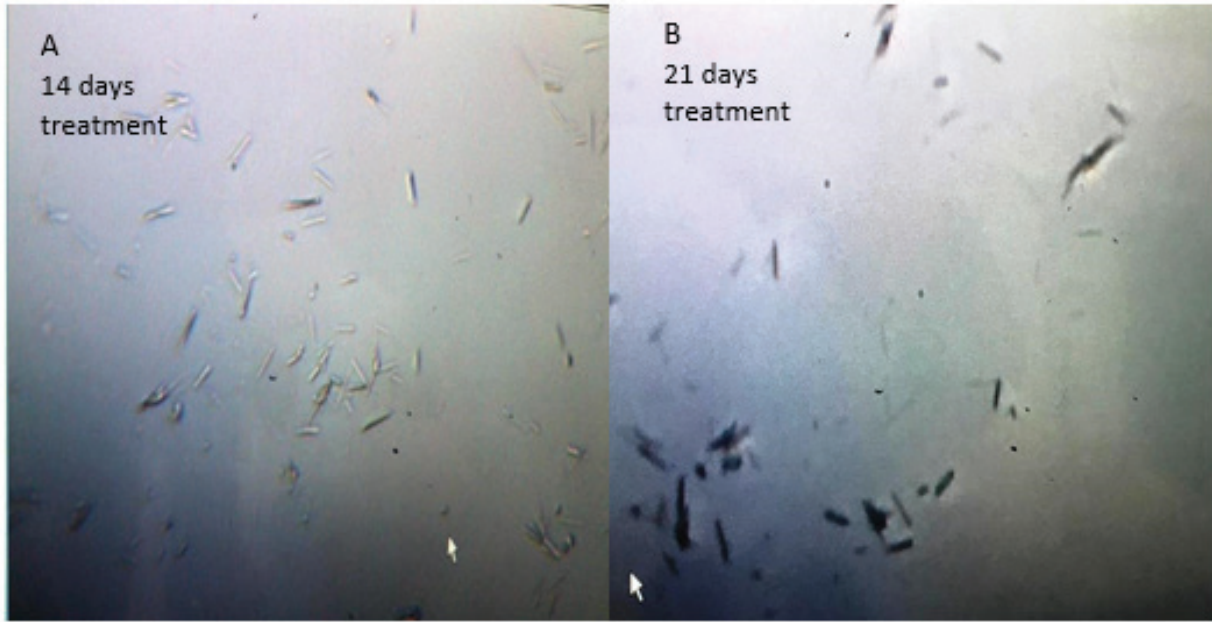
**Figure 1:** Histogram of AmmiVisnaga alcoholic extract showing the main chemical compounds.

### Urine Crystallization:

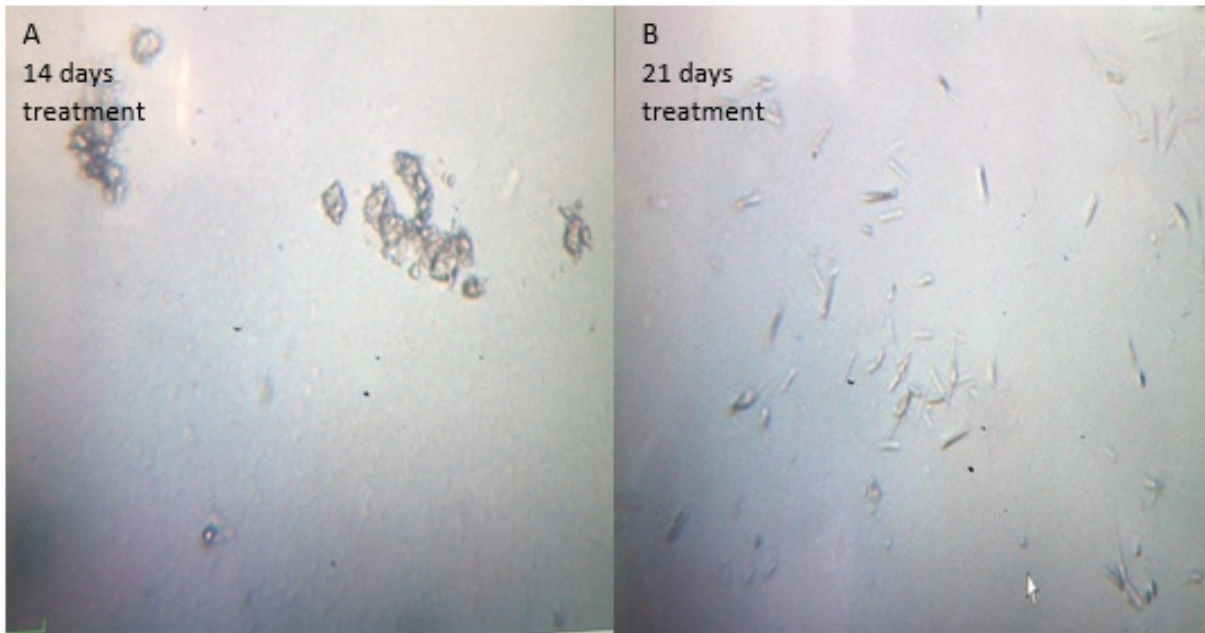
After 14 days and 21 days from induction, urinary lithiasis groups showed clear crystallization compared to the control urine samples, but after 14 days treatment with AmmiVisnaga and proximol extracts, there was nearly clearance of the urine and disappearance of the crystals from the urine as shown in figures 7, 8, 9, 10.



**Figure 2:** Image of urine samples collected in the morning from rabbits (A) control group (B) lithogenic group after 14 days of induction showing clear crystals and (C) lithogenic group after 21 days of induction showing severe crystallization. Investigated using the high power field (HPF), under light microscope at 400 X magnification.



**Figure 3: Image of urine samples collected in the morning from rabbits after treatment by AmmiVisnaga extract (A) for 14 days and (B) for 21 days showing disappearance of crystallization Investigated using the high power field (HPF), under light microscope at 400 X magnification.**



**Figure 3: Image of urine samples collected in the morning from rabbits after treatment by proximol extract (A) for 14 days and (B) for 21 days showing partial disappearance of crystallization Investigated using the high power field (HPF), under light microscope at 400 X magnification.**

## Discussion

Results of this study showed that urine crystals formation induced by drenching ethylene glycol and ammonium chloride caused damage to the renal tissue, as in previous studies<sup>11, 12</sup>. This damage might induced by the reactive oxygen species (ROS) which is regarded as the dangerous material produced by the crystals deposited in the renal tissue forming renal calculi<sup>9</sup>.

In this study AmmiVisnaga extract induced significant rise in urine production (diuresis effect) compared to the control group, this may be due to the diuretic materials found in AmmiVisnaga extract which may possess several treatmental actions present in several phytochemicals. So diuretic effect of AmmiVisnaga increases urine amount is voided leading to decrease urine saturation of salts crystals and help in discharging out of the previously formed crystals<sup>16,17</sup>. Previous studies on AmmiVisnaga revealed removing of DPPH free radicals and caused inhibition of fat peroxidation assisting its antioxidant properties<sup>13-15</sup>.

In this experiment high calcium oxalate crystals were induced in the kidney by ethylene glycol (0.75% in the drenching water) for 21 days and ammonium chloride (1%) was given only for the first 5 days, as drenching ammonium chloride for more than 5 days will causes severe weight loss and may result in rabbits death<sup>18</sup>. Drenching of ethylene glycol and ammonium chloride causes more crystallization in the urine as well as forms larger crystals because of hyperoxaluria. Higher water consumption and more urine excretion may happened because of kidney damage<sup>19</sup>. Furthermore, there was significant rise in the serum creatinine, blood urea and total protein loss in the lithogenic group when compared to the control group, these overcome by AmmiVisnaga and Proxamol extracts.

These results in cope with other past results recorded that crystallization of salts in the urine caused by increase in oxalate consumption and less calcium excretion in the group of induced urolithiasis was overcome by drenching AmmiVisnaga extract<sup>20, 21</sup>.

AmmiVisnaga accelerate the recovery compared to untreated group which was obviously seen by improvement in the body weight, high clearance in urine crystals and amelioration in kidney function compared to untreated group.

This study provided us with a good knowledge on the treatment bases and its action in the urinary calculi or stones. Furthermore, the plant can be considered as safe. Previous study found no toxic effect of AmmiVisnaga extract on rats and the plant has a good history of medical uses consumed by human and regarded safe and nontoxic<sup>22</sup>.

Result of Table 1 showed a significant effects of lithogenic treatment on blood urea, serum creatinine, uric acid and serum calcium and their overcoming and ameliorative effects by both AmmiVisnaga and proxamol. Those result are consistent with previous studies on sheep<sup>23</sup> and on rats<sup>24</sup>.

The significant increase in serum calcium level in this study due to lithogenic treatment may be due to calcium reuptake under the effect of aldosterone<sup>25</sup>. This explanation supported by reduction of serum calcium level by AmmiVisnaga and proxamol significantly nearly to the control. Therefore, the dose of AmmiVisnaga extract and Proxamol need to be adjusted or refined in the case of combined treatment.

The results of this study indicates that there is a bad effect on the Kidney function caused by the lithogenic effect indicated by significant increase in the blood urea, serum creatinine and uric acid as well as serum calcium, these effects are ameliorated by AmmiVisnaga extract and Proxamol. These results are consistent with the results of previous study<sup>25</sup>, and with other study that explained high salt consumption resulted in the formation of kidney damage, which may lead to Kidney failure<sup>26</sup>.

When rabbits with renal impairments treated with AmmiVisnaga or proxamol extracts, the high serum level of uric acid, creatinine and blood urea were regressed to the non-significant levels in comparison with the control.

Other parameter such as ketone bodies, PH, protein, Nitrite and bilirubin were increased due to lithogenic formation. Treatment with AmmiVisnaga or Proximol extracts ameliorate these parameters and restore their concentration to nearly normal levels due to their diuretic, antioxidant, anti-inflammatory and antispasmodic effects.

### Conclusion

In conclusion, AmmiVisnaga and Proximol are safe and good diuretic herbs causes improvement in the body weight, high clearance in urine crystals and amelioration in kidney function compared to untreated group.

**Acknowledgments:** This study is a part of M.Sc. thesis submitted to the Department of Physiology, College of Veterinary Medicine, and University of Basrah. The authors acknowledge the college for encouragement and support.

**Conflicts of Interest:** The authors state that they have no conflicts of interest.

**Ethical Statement:** All tests performed in agreement with the National Institute of Health Guidelines for the Treatment and Use of Laboratory Animals (86/609/EEC) and permitted by Basrah University, College of Veterinary Medicine Ethical Committee.

### References

1. Butterweck V, Khan SR. Herbal medicines in the management of urolithiasis: alternative or complementary? *Plantamedica*. 2009 Aug;75(10):1095. Herbal medicines in the management of urolithiasis: alternative or complementary? - PubMed (nih.gov)
2. Gürocak S, Küpeli B. Consumption of historical and current phytotherapeutic agents for urolithiasis: a critical review. *The Journal of urology*. 2006 Aug;176(2):450-5 Consumption of historical and current phytotherapeutic agents for urolithiasis: a critical review - PubMed (nih.gov).
3. Hess B. Pathophysiology, diagnosis and conservative therapy in calcium kidney calculi. *Therapeutische Umschau. Revue thérapeutique*. 2003 Feb 1;60(2):79-87. [Pathophysiology, diagnosis and conservative therapy in calcium kidney calculi] - PubMed (nih.gov)
4. Mattle D, Hess B. Preventive treatment of nephrolithiasis with alkali citrate—a critical review. *Urological research*. 2005 May 1;33(2):73-9. Preventive treatment of nephrolithiasis with alkali citrate—a critical review - PubMed (nih.gov)
5. Gilani AH. Trends in ethnopharmacology. *Journal of ethnopharmacology*. 2005 Aug 22;100(1-2):43-9. Trends in ethnopharmacology - PubMed (nih.gov)
6. Williamson EM. Synergy and other interactions in phytomedicines. *Phytomedicine*. 2001 Jan 1;8(5):401-9. Synergy and other interactions in phytomedicines - PubMed (nih.gov)
7. Batanouny KH, Aboutabl E, Shabana M, Soliman F. *Wild medicinal plants in Egypt*. The Palm press, Cairo; 1999.
8. Keddad A, Baaliouamer A, Hazzit M. Chemical Composition and Antioxidant Activity of Essential Oils from Umbels of Algerian Ammivisnaga (L.). *Journal of Essential Oil Bearing Plants*. 2016 Jul 3;19(5):1243-50.
9. Byer K, Khan SR. Citrate provides protection against oxalate and calcium oxalate crystal induced oxidative damage to renal epithelium. *The Journal of urology*. 2005 Feb;173(2):640-6.
10. Omar AR, El-Din EY, Abdelrahman HA. Implications arising from the use of *Cymbopogon proximus*; proximal on placenta of pregnant Albino rats. *Brazilian Archives of Biology and Technology*. 2016;59.
11. Aihara K, Byer KJ, Khan SR. Calcium phosphate-induced renal epithelial injury and stone formation: Involvement of reactive oxygen species. *Kidney International*. 2003 Oct 1;64(4):1283-91.
12. Escobar C, Byer KJ, Khaskheli H, Khan SR. Apatite induced renal epithelial injury: insight into the pathogenesis of kidney stones. *The Journal of urology*. 2008 Jul;180(1):379-87.
13. Lin SP, Tsai SY, Lin YL, Kuo SC, Hou YC, Chao PD. Biotransformation and Pharmacokinetics of 4-(3, 4-Dihydroxybenzoyloxymethyl) phenyl-O-β-d-glucopyranoside, an Antioxidant Isolated from *Origanum vulgare*. *Journal of agricultural and food chemistry*. 2008 Apr 23;56(8):2852-6.
14. Matsuura H, Chiji H, Asakawa C, Amano M, Yoshihara T, Mizutani J. DPPH radical scavengers

- from dried leaves of oregano (*Origanum vulgare*). *Bioscience, biotechnology, and biochemistry*. 2003;67(11):2311-6.
15. Srihari T, Sengottuvelan M, Nalini N. Dose-dependent effect of oregano (*Origanum vulgare* L.) on lipid peroxidation and antioxidant status in 1, 2-dimethylhydrazine-induced rat colon carcinogenesis. *Journal of Pharmacy and Pharmacology*. 2008 Jun;60(6):787-94.
  16. Dasaeva LA, Shilov EM, Shatokhina SN. Diuresis for the treatment of early stages of urolithiasis. *Klinicheskaiameditsina*. 2003;81(10):50-2.
  17. Goldfarb DS, Coe FL. In AM Davison, JS Cameron, E. Ritz, J. Grünfeld, C. G. Winearls, C. Ponticelli & CV The medical management of stone disease. In *Oxford textbook of clinical nephrology 2005* (pp. 1199-1279). Oxford University Press.
  18. Vanachayangkul P, Chow N, Khan SR, Butterweck V. Prevention of renal crystal deposition by an extract of *Ammivisnaga* L. and its constituents khellin and visnagin in hyperoxaluric rats. *Urological research*. 2011 Jun 1;39(3):189-95.
  19. Bashir S, Gilani AH. Antiurolithic effect of berberine mediated through multiple pathways. *European journal of pharmacology*. 2011 Jan 25;651(1-3):168-75.
  20. Fan J, Glass MA, Chandhoke PS. Impact of ammonium chloride administration on a rat ethylene glycol urolithiasis model. *Scanning Microsc*. 1999;13(2-3):299-306.
  21. Park HK, Jeong BC, Sung MK, Park MY, Choi EY, Kim BS, Kim HH, Kim JI. Reduction of oxidative stress in cultured renal tubular cells and preventive effects on renal stone formation by the bioflavonoid quercetin. *The Journal of urology*. 2008 Apr;179(4):1620-6.
  22. Koriem KM, Arbid MS, El-Attar MA. Acute and subacute toxicity of *Ammivisnaga* on rats. *Interdisciplinary toxicology*. 2019 Sep 1;12(1):26-35.
  23. Maciel TA, Ramos IA, da Silva RJ, Soares PC, Carvalho CC, Júnior RJ, Amoroso L, Artoni SM, Afonso JA, Oliveira D. Clinical and biochemical profile of obstructive urolithiasis in sheep. *Acta Scientiae Veterinariae*. 2017;45:1-5.
  24. Khan A, Bashir S, Khan SR, Gilani AH. Antiurolithic activity of *Origanum vulgare* mediated through multiple pathways. *BMC complementary and alternative medicine*. 2011 Dec;11(1):1-6.
  25. Radwan SA, Khadrawy YA, Sakr SM, Abdel-Bakey ES. The Therapeutic Role of Proxamol and Lasilactone in Rat Model of Renal Stress. *The Egyptian Journal of Hospital Medicine*. 2015 Apr 1;59(1):233-43.
  26. Durack E, Alonso-Gomez M, Wilkinson MG. Salt: a review of its role in food science and public health. *Current Nutrition & Food Science*. 2008 Nov 1;4(4):290-7.