

# Mastoid Canals and Grooves in Human Skulls: A Dry Bone Study

UshaVerma<sup>1</sup>, Shavi Garg<sup>2</sup>, Amit Kumar Saxena<sup>3</sup>, RituSingroha<sup>4</sup>, Prachi SAneja<sup>5</sup>, Suresh KantaRathee<sup>6</sup>

<sup>1</sup>Assistant Professor, Deptt. of Anatomy, Pt. B.D. Sharma PGIMS, Rohtak, Haryana, <sup>2</sup>Associate Professor, Deptt. of Anatomy, SGT Medical College, Gurugram, Haryana, <sup>3</sup>Professor and Head, Deptt. of Anatomy, Autonomous State Medical College, Shahjahanpur, U.P, <sup>4</sup>Professor, Deptt. of Anatomy, Pt. B.D. Sharma PGIMS, Rohtak, Haryana, <sup>5</sup>Professor and Head, Deptt. of Anatomy, SGT Medical College, Gurugram, Haryana, <sup>6</sup>Senior Professor and Head, Deptt. of Anatomy, Pt. B.D. Sharma PGIMS, Rohtak, Haryana

## Abstract

**Background:** The mastoid canals and mastoid grooves are formed within the mastoid part of temporal bones of skull, these are present on the external surface of mastoid region, anterior to the occipitomastoid suture, behind and parallel to the petrosquamous suture and anteroinferior to the asterion. The study was conducted to observe the incidence of mastoid canals and grooves in dry adult human skulls.

**Methods:** Total of 120 dry adult human skulls consisting of 80 male & 40 female were examined to determine the incidence of mastoid canals and grooves. The mastoid parts of both sides were examined for the presence of mastoid canals and grooves. Then length of mastoid canals was measured.

**Conclusion:** Out of the total of 120 skulls, mastoid canals were observed in 8.75% of skulls. The incidence of mastoid canals was 10% in females and 8.12% in males. The incidence of mastoid grooves was 10.42% of total skulls. It was 11.88 % in male skulls and in female skulls, it was 7.55%. The knowledge of mastoid canals and grooves of the temporal bones is very useful to the neurosurgeons and ENT surgeons while doing surgery to avoid severe bleeding.

**Key words:** Mastoid grooves, Mastoid canals, Skull

## Introduction

The mastoid canals and mastoid grooves are formed within the mastoid part of temporal bones of skull, these are present on the external surface of mastoid region, anterior to the occipitomastoid suture,

behind and parallel to the petrosquamous suture and anteroinferior to the asterion. The mastoid canals are of variable diameter and length, and the knowledge of them is very useful for neurosurgeons and ENT surgeons. As they have an arterial branch of occipital artery with its associated vein, which can be injured and can cause severe bleeding. It is probable that during development of the mastoid process, the squamous part of temporal bone ossifies over the vessels, giving rise to the mastoid canals(Schaefer JP,1953 and Hollinshead WH, 1982). Therefore, the study was conducted to observe the incidence of mastoid canals and grooves in dry adult human skulls.

---

### Corresponding author:

**Dr. RituSingroha**

H. No. 15/9-J, Medical Campus

Rohtak, Haryana, India

Mob. No.:- 08607703777

Email ID:- ritusingroha@gmail.com

## Materials and Methods

Total of 120 dry adult human skulls consisting of 80 male & 40 female skulls were examined to determine the incidence of mastoid canals and grooves. The skulls were retrieved from the department of Anatomy, PT. B.D. Sharma PGIMS, Rohtak. The study was conducted in the year 2019-20. The study was conducted after ethical clearance from the Institutional Ethics Committee. The mastoid parts of both sides were examined for the presence of the mastoid canals and grooves. A thin metallic wire was passed through the canal for its confirmation. Then, the length of mastoid canals was measured with the help of the digital vernier caliper.

## Results and Discussion

Out of the total 120 skulls, the mastoid canals were observed in 8.75% (21) of total skulls (Table-1, Fig.-1). The mastoid canals were observed 10% (13) in female skulls and in male skulls, it was 8.12% (8). In 3 male skulls and in 1 female skull mastoid canals were present bilaterally.

The lengthwise measurement of mastoid canal in male skulls on the right side was 2.01 -12 mm and in female skulls it was 5.6 -14 mm. In male skulls on the left side it was 3.85 -13.51 mm and in female skulls it was 1.1 -11.8 mm (Table-2).

In this study, the incidence of mastoid grooves was 10.42% (25) of total skulls. It was 11.88 % (19)

in male skulls and in female skulls, it was 7.55% (6) (Table-3, Fig.-2).

Both the mastoid canals and grooves were found bilaterally in one male skull.

In the present study, the incidence of the mastoid canal was 8.75 % which is in consensus with the study performed by Choudhry et al. 1996. In the Japanese skulls, Singh et al. 2004 reported the incidence of the mastoid canal as 52.4% while in the South Indian skulls the incidence of mastoid canal was reported as 59.2% by Hussain et al. 2012. Hadimani and Bagoji, 2013 on North Karnataka skulls reported it as 53% (Table-4).

The incidence of the mastoid groove was less in this study (10.42%) when compared to the results on others. Singh et al. 2004 reported that the incidence of the mastoid groove was 13.56% in the Japanese skulls. And it was 18% in the North Karnataka skulls reported by Hadimani and Bagoji, 2013 while it was 20% in the South Indian skulls reported by Hussain et al. 2012 and according to Saadia et al. 2016 it was 24% in the Egyptian skulls (Table-4).

In this study both mastoid canal and groove was observed on the same side in 1 male skull while the incidence of both mastoid canal and groove on the same side was 2% as reported by Hadimani and Bagoji, 2013 on the North Karnataka skulls.

**Table No. 1 Incidence of Mastoid Canals in Males and Females**

Gender	Present (%)	Absent (%)	Total
Male (n =160)	13 (8.12 %)	147 ( 91.88 %)	160 (100%)
Female (n = 80)	8 (10 %)	72 (90 %)	80 (100%)
Total	21 (8.75 %)	219 (91.25%)	240 (100%)

**Table No. 2 Incidence of Length of Mastoid Canals in Males and Females**

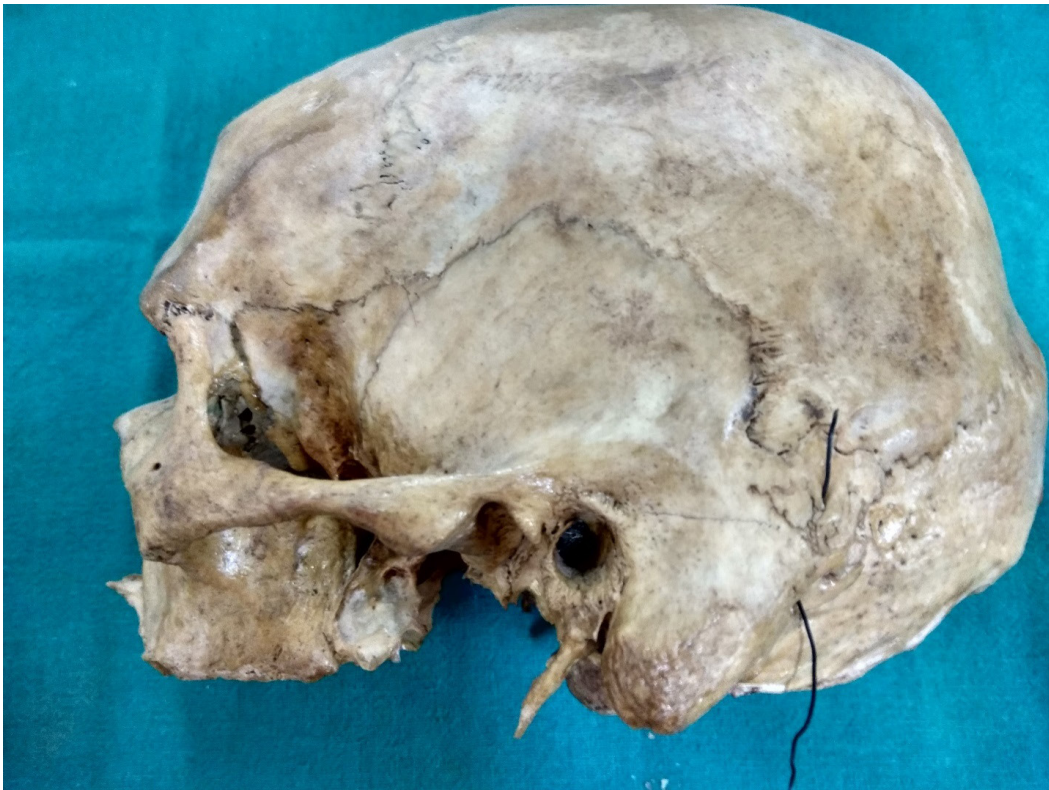Gender	Right Side		Left Side		Total
	1-10 mm	11-20 mm	1-10 mm	11-20 mm	
Male (n=160)	4 (2.5 %)	2 (1.5 %)	4 (2.5 %)	3 (1.9%)	13 (8.12%)
Female (n=80)	2 (2.5 %)	2 (2.5%)	3 (3.8 %)	1 (1.25%)	8 (10 %)
Total (n=240)	6 (2.5 %)	4 (1.7%)	7 (2.9 %)	4 (1.7 %)	21 (8.7%)

**Table No. 3 Incidence of Mastoid Grooves in Males and Females**


Gender	Present (%)	Absent (%)	Total
Male (n =160)	19 (11.88 %)	141 ( 88.12 %)	160 (100%)
Female (n = 80)	6 (7.5 %)	74 (92.5% )	80 (100%)
Total	25 (10.42 %)	215 (89.58%)	240 (100%)

**Table No. 4 Incidence of Mastoid Canals and Grooves as observed in the Present Study and Compared the Same with Earlier Studies**

Author	Choudhry et al[3]	Singh et al[4]	Hussain et al[5]	Hadimani et al[6]	Saadia et al[7]	Present study
Population	Indian	Japanese	South -Indian	North Karnataka	Egyptian	North Indian
No. of Skulls	265	435	125	100	100	120
Mastoid Canals Present	7.7%	52.4%	59.2%	53%	28%	8.75%
Mastoid Grooves Present	-	13.56%	20%	18%	24%	10.42%



**Figure 1: Wire passing through mastoid canal**



**Figure 2: Red arrow indicating on mastoid groove**

### **Conclusion**

The knowledge of the mastoid canals and grooves of temporal bones is very useful to the neurosurgeons and ENT surgeons due to increasing use of the transtemporal route for surgeries relating to structures in the posterior cranial fossa and the mastoid air system. As the mastoid canals and grooves have an arterial branch of occipital artery with its associated vein, it can be injured and can cause severe bleeding when they are doing surgery.

**Ethical Clearance** – Taken from the Institutional Ethics Committee vide letter No. SGTU/FMHS/D/795 Dated 26. Nov. 2018.

**Source of Funding-** NIL

**Conflict of Interest-** NIL

### **References**

1. Schaefer JP. Morris' Human Anatomy. 11th ed. New York: Blakiston; 1953. p. 166.
2. Hollinshead WH. Anatomy for Surgeons the Head and Neck. 3rd ed. Vol. 1. New York: Harper and Row; 1982. p. 183.
3. Choudhry R, Raheja S, Gaur U, Anand C. Mastoid canals in adult human skulls. *Journal of Anatomy* 1996;188:217–19.
4. Singh M, Mishra A, Nagashima M. Mastoid Canals and Grooves in adult Japanese human skulls. *J Anat Soc India* 2004;53(2):40–3.
5. Hussain SS, Muralidhar PS, Desai SD, Thomas ST, Maavishettar GF, Haseena S. Study of Mastoid canals and grooves in South Indian skulls. *IJMHC* 2012;1(1):32–3.
6. Hadimani GA and Bagoji IB. Study of Mastoid Canals And Grooves in North Karnataka Human Skulls. *J Clin Diagn Res* 2013;8:1537-9.
7. Saadia A, Shalaby, Essam M, Eid, Omar A. Morphometric Study Of Mastoid Canal And Suprameatal Triangle Of Human Egyptian Skull, With Gender Determination. *Nature and Science* 2016;14(4):67-73.