

Pneumonitis Following Diesel Oil Siphonage: A Case Series

Komal Gharsangi¹, Parul², Rajesh Bhawani³

¹Assistant Professor, ²Senior Resident, ³Professor, Department of General Medicine,
Shri Lal Bahadur Shastri Govt medical college Nerchowk HP-175008

How to cite this article: Komal Gharsangi, Parul, Rajesh Bhawani. Pneumonitis Following Diesel Oil Siphonage: A Case Series. Indian Journal of Forensic Medicine and Toxicology 2023;17(1).

Abstract

Manual siphoning of diesel with mouth from automobiles is common practice in rural communities. This practice can be hazardous leading to ingestion and aspiration of diesel leading to chemical pneumonitis. Here we present two cases of chemical pneumonitis following siphonage of diesel managed with steroids and recovered completely.

Keywords: diesel, siphonage, pneumonitis

Introduction

Diesel siphoning through rubber tubing from the automobiles is a very common practice in rural areas which can be hazardous leading to chemical pneumonitis. Diesel is a mixture of long chain saturated hydrocarbons which disrupt surfactants and cause direct inflammatory response in lungs leading to lung injury. Diesel ingestion usually results in transient vomiting, diarrhoea, and abdominal pain. ¹ In the local injury it can cause chemical burns in the oral cavity. Most patients recover without any significant pulmonary sequelae in chemical pneumonitis due to diesel siphonage.

Case 1

A 28 year old male patient presented to emergency with accidental inhalation of diesel while siphoning from his vehicle 4 hours back. His chief

complaints were of fever, breathlessness, cough and chest pain. His past medical and surgical history were uneventful. On examination his temperature was 37.2°C, heart rate was 106/min, blood pressure was 100/70 mmHg, respiratory rate was 28/min with oxygen saturation of 91% on room air with non-invasive pulse oximetry. Blood parameters showed leucocytosis of 13300/cumm while his renal and liver function tests were within normal limits. X ray showed infiltrations in bilateral lower lobes. Patient was given oxygen through face mask intermittently and started on inj. ceftriaxone and inj. dexamethasone 6 mg iv once daily which was continued for 7 days. Patient showed improvements in terms of reduced respiratory rate and oxygen saturation 95% on room air with no further oxygen requirement. Patient was discharged on 10th day and followed up in the outpatient department.

Corresponding Author: Komal Gharsangi, Assistant Professor, Department of General Medicine, Shri Lal Bahadur Shastri Govt medical college Nerchowk HP-175008.

E-mail: drshinny@gmail.com

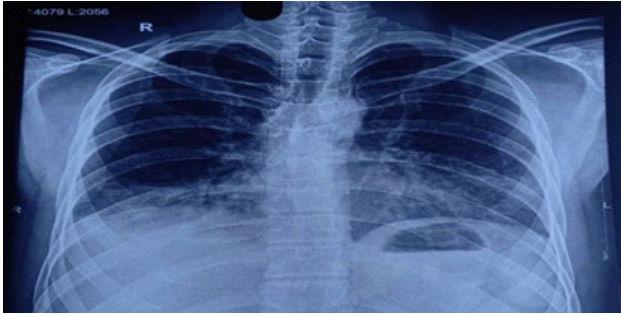


Figure 1

Patient's CXR revealing opacifications and infiltrations over the right lower, and left lower lung fields.

Case 2

A 24 year old male patient presented to emergency with complaints of chest pain, breathlessness and dry cough. Patient has history of diesel siphoning two days back. Patient has a heart rate of 120/min, blood pressure of 120/78 mmHg, respiratory rate of 40/min, oxygen saturation on room air of 88-89%. Patient has harsh breath sounds on right side of chest on auscultation. His blood reports showed leucocytosis of 11500/cumm and chest X-ray showed infiltrates in the right lower lobe only. Patient was given oxygen therapy with venturi mask and started on antibiotics and inj. dexamethasone 6 mg i.v once a day. Patient was continued with steroids for 10 days and stopped when there was improvement in symptomatology. Patients respiratory rate improved and no longer needed oxygen therapy.

Discussion

Diesel is distilled from petroleum and is commonly used as fuel for engines. Diagnosis of patients who may have undertaken diesel siphonage depends on three criteria: presence of pulmonary symptoms following an episode of siphonage, typical manifestations on radiologic investigations (CXR or chest CT) with suspected history, and lipid-laden macrophages on BAL or pathologic findings.² Diesel causes surfactant destruction which result from inflammatory reaction due to activation of macrophages and release of inflammatory cytokines.³ Yi-jung Chen et al reviewed 15 articles, which included 3 original articles and 12 case reports and reported that most cases were among men and the age range of patients was 18-64 years. Most patients became symptomatic within 1 day of fuel siphonage

and clinical features of fuel siphonage as cough, chest pain, dyspnoea, fever were present in more than half of all patients. Leukocytosis was a common finding in most patients. In imaging the right middle lobe was the predominantly involved lung field followed by right lower lobe.⁴ In our cases also both the patients were young male with blood leucocytosis and bilateral lower lobe infiltrations. Supportive care and treatments with intravenous antibiotics, steroids are common therapies. Sen et al reported in their retrospective study that patients with hydrocarbon pneumonitis responded well to steroid therapy.⁵ Use of steroids is thought to limit inflammation and fibrosis. But still the role of antibiotics and steroids is controversial in these cases.

Conclusion

Chemical pneumonitis by diesel siphonage rarely causes severe morbidity, or mortality in patients but this should be prevented by educating people and making them aware about the hazards of such practices.

Funding: None

Conflicts of interest: None

Acknowledgement: None

Ethical approval: Approved

References

1. Tormoehlen LM, Tekulve KJ, Nañagas KA. Hydrocarbon toxicity: A review. *Clin Toxicol (Phila)* 2014;52(5):479-89.
2. Marchiori E, Zanetti G, Mano CM, Irion KL, Daltro PA, Hochhegger B. Lipoid pneumonia in 53 patients after aspiration of mineral oil: comparison of high-resolution computed tomography findings in adults and children. *J Comput Assist Tomogr.* 2010;34(1):9-12.
3. E. Grossi, E. Crisanti, G. Poletti, V. Polett. Fire eater's pneumonitis. *Monaldi Arch Chest Dis*, 65 (2006), pp. 59-61
4. Yi-jung Chen, Chien-chin Hsu, Kuo-tai Chen. Hydrocarbon pneumonitis following fuel siphonage: A case report and literature review. *World J Emerg Med.* 2019; 10(2): 69-74.
5. Sen V, Kelekci S, Selimoglu Sen H, Yolbas I, Günes A, Abakay O, et al. An evaluation of cases of pneumonia that occurred secondary to hydrocarbon exposure in children. *Eur Rev Med Pharmacol Sci.* 2013;17(Suppl 1):9-12.