

Canine Menace: A Case Report

R. Varun Kumar¹, M. Taqiuddin Khan²

¹Second Year Post Graduate, Department of Forensic Medicine and Toxicology, Osmania Medical College, Hyderabad, India, ²Professor, Department of Forensic Medicine and Toxicology, Osmania Medical College, Hyderabad, India.

How to cite this article: R. Varun Kumar, M. Taqiuddin Khan. Canine Menace: A Case Report. Indian Journal of Forensic Medicine and Toxicology / Volume 18 No. 1, January-March 2024.

Abstract

A 13 years old male found dead with several bite marks in the body, with some 8 to 10 dogs around that area. The deceased body was brought to Mortuary, Osmania General Hospital at 03:30 PM on 19/05/2022 by the Investigation Officer and requested for postmortem examination under section 174 Criminal Procedure Code. On postmortem examination, there were multiple claw marks, avulsed lacerations, puncture wounds present all over the body, laceration of platysma and a retro-laryngeal hematoma with fracture of 6th cervical vertebrae were noted, all were suggestive of canine tooth injury. All the internal organs were pale and cause of death was given as massive haemorrhage consequent to animal bites over head, neck and trunk.

Keywords: Avulsed laceration, Claw marks, Multiple puncture wounds, Retropharyngeal hematoma, Massive hemorrhage.

Introduction

- Dogs usually bite when they are provoked / aggressive. The following are the common aggressions^[1]

Sexual aggression

Maternal aggression

Food aggression

Fear aggression

Territorial aggression

Aggression due to rabies

- Rabies in dogs is due to LYSSA virus which affects a dog's central nervous system, spinal

cord and brain. It initially settles in the muscle tissue and moves to the dog's nervous system, ultimately entering salivary glands. It will kill the animal host in nearly 100% cases. Virus cannot survive for longer than 24 hours outside the host.^[2]

- Dogs are the most common carriers of Rabies. Other common carriers of rabies are fox, bats, skunks and racoons. Rabies spread through saliva coming out from another affected animal. Dogs are more prone to catching the infection if they have a scratch, laceration or an open wound. To humans it is transmitted by bite of the affected animal.^[2]

- **10 signs of rabies in dogs:**^[3]

Corresponding Author: R. Varun Kumar, Second year Post Graduate, Department of Forensic Medicine and Toxicology, Osmania Medical College, Hyderabad, India.

E-mail: varun.cmchrc@gmail.com

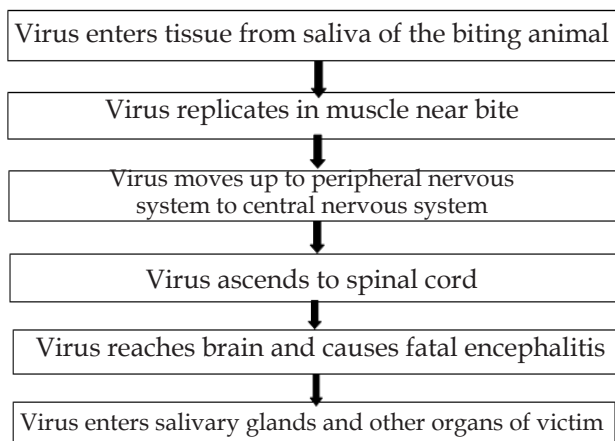
Submission Date: July 5, 2023

Revision Date: August 11, 2023

Published Date: 2024-01-18

- Restlessness
 - Withdrawal
 - Licking the bite
 - Aggression
 - Furiousness
 - Dilated pupils
 - Seizures
 - Lack of fear
 - Salivating
 - Paralysis
- } Final stage symptoms

- The farther away from brain, the longer virus takes to spread through central nervous system.
- Pathway for ascend in humans:^[4]



- Symptoms in human: ^[4]
 - Fever
 - Depression
 - Agitation
 - Painful spasms followed by excessive saliva - Foaming at mouth after drinking water.
 - Death within week without vaccine
 - **Treatment: Hospitalisation, Immunoglobulin injections, anti-rabies vaccine.**

THE CASE:

- On 19th of may at around 3:30 pm, we received an inquest from station house officer of Kulsumpura police station of Hyderabad city police division. As per the police inquest, at around 12:30 pm on the same day. Two persons, in the bank of Moosi river, saw an unknown male aged around 10-15 years, found lying unconscious with several bite

marks in the body, with some 8 to 10 dogs around that area. They both immediately informed it to the police. Later, father of the deceased confirmed that the deceased person is Master. xxxxxx, his 13-year-old son. According to his statement, his son used to play with his friends usually in that area and on that particular day as his friends were not there, he went for fishing in that river and later found dead. Case was filed under section 174 Criminal procedure code and the corpse was brought for autopsy to Osmania General Hospital and requisition for autopsy was submitted by the Investigation officer and autopsy was conducted on the same day.

CRIME SCENE:




Fig 1. Clues team tags in crime scene



Fig 2. Body found away from belongings

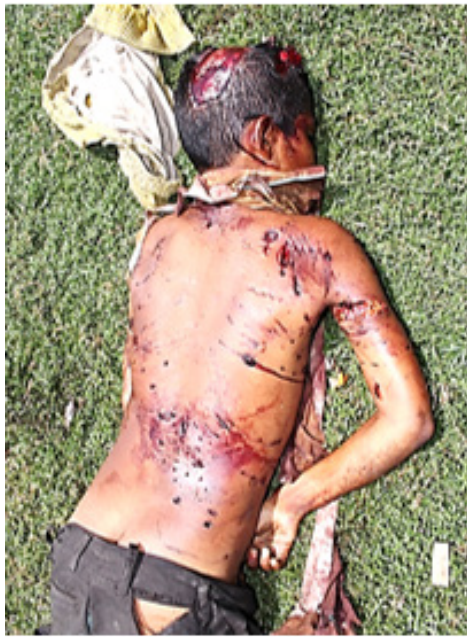

Fig 3. Position altered in the crime scene.

➤ **POST MOTEM EXAMINATION:**

❖ An average built male aged about 13 years with height of 142cm {Fig 4}. Body was dressed in Olive green colour floral designed shirt, soaked in blood, ragged and tattered, dark green colour pant torn at outer thigh, belt, leg and buttocks region {Fig 5}. Body was supine, eyes closed, mouth partly closed, wild dried green leaf twigs present all over the body. Dried blood stains present over face, neck, upper part of chest, both the upper limbs and both feet. Skin peeling was present at multiple areas. Penis was circumcised. Rigor mortis developed over upper limbs and Post-mortem Lividity could not be appreciated {Fig 6}.

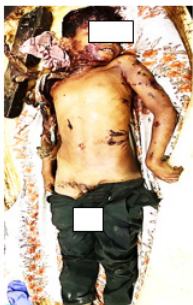

Fig 4. Body of the deceased

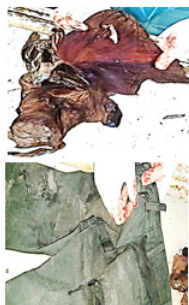

Fig 5. Clothes

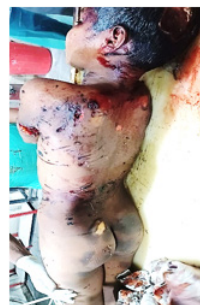

Fig 6. Post-mortem lividity not appreciated

❖ Multiple scalp deep avulsed laceration were present over temporoparietal region of both sides of the head. Multiple scalp deep lacerations were also noted all over the head {Fig 7,8}. The margins of all injuries were irregular in shape with evidence of skin tags. On reflection of skin over the scalp, contusion of size 7cm x 4cm was present 2cm in front of left parietal region {Fig 9}. Contusion of size 14cm x 10cm was present over the right parietal region extending up to left occipital region on the back.

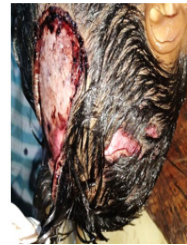

Fig 7. Avulsed laceration



Fig 8. Avulsed laceration

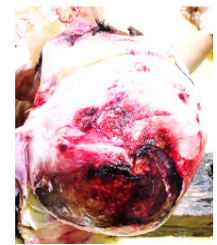

Fig 9. Skull after reflection of scalp

❖ Claw marks overlapping each other, 1cm apart below the left ear lobule tip with 2 skin deep lacerations present over the left side of neck {Fig 10}. Multiple skin-deep puncture wounds were present over the right side of neck from midline extending up to 6cm below the right ear lobule {Fig 11}. Multiple skin-deep punctured wounds were present over the upper and mid part of neck.

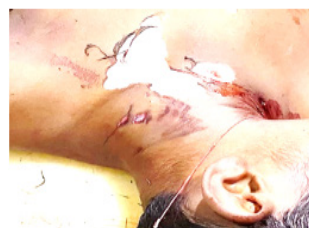

Fig 10. Claw marks over left side of neck

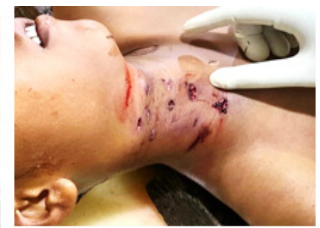

Fig 11. Puncture wounds over right side of neck

❖ On reflection of skin internally, a contusion with underlying laceration of platysma and a retro-laryngeal hematoma with fracture of 6th cervical vertebrae were noted, all were suggestive of canine tooth injury {fig 12 to 14}

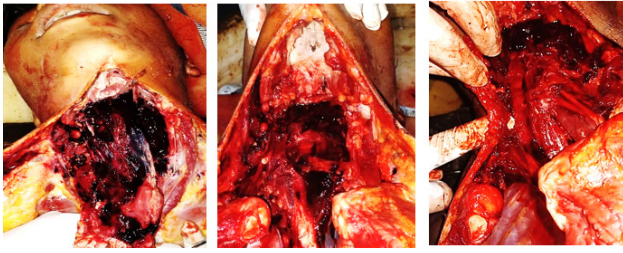


Fig 12. Retropharyngeal hematoma **Fig 13. Lacerated platysma** **Fig 14. Depicting a puncture wound**

❖ Chest: Multiple claw marks along with multiple muscle deep lacerations were noted {Fig 15,16}.

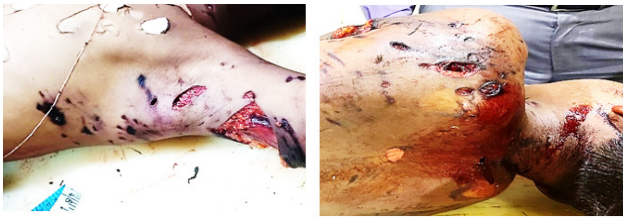


Fig 15. Claw marks in chest **Fig 16. Muscle deep lacerations over back of chest**

❖ Abdomen: Multiple claw marks with muscle deep lacerations were noted {Fig 17}.

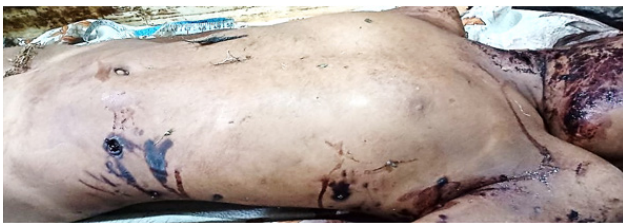

Fig 17. Claw marks with lacerations in abdomen.

❖ Right Upper Limb: multiple skin deep puncture wounds and multiple skin deep lacerations were noted {Fig 18}.

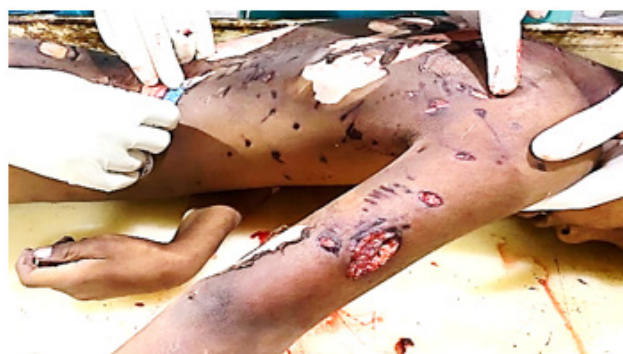

Fig 18. Puncture wounds in right upper limb

❖ Left upper Limb: Multiple skin deep puncture wounds and Multiple muscle deep lacerations were noted.

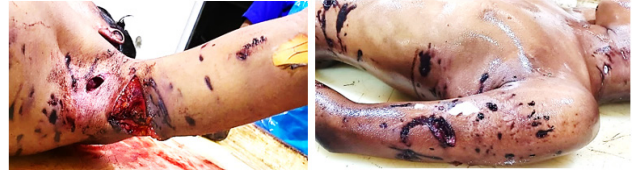

Fig 19. Skin deep puncture wounds in left upper limb **Fig 20. Muscle deep lacerations in left upper limb**

❖ Back: Multiple claw marks and multiple skin deep puncture wounds were noted.

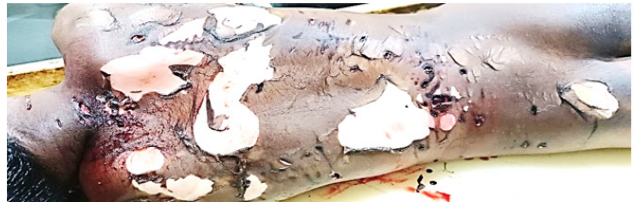


Fig 21. Skin deep puncture wounds over the back

❖ Lower limbs: Multiple Muscle deep bite marks were noted over front and back of both the lower limbs.

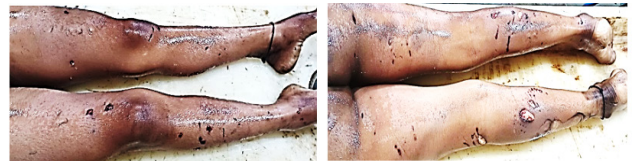

Fig 22. Muscle deep bite marks over front of lower limbs **Fig 23. Muscle deep bite marks over back of lower limbs**

❖ Internally all the organs appeared extremely pale.

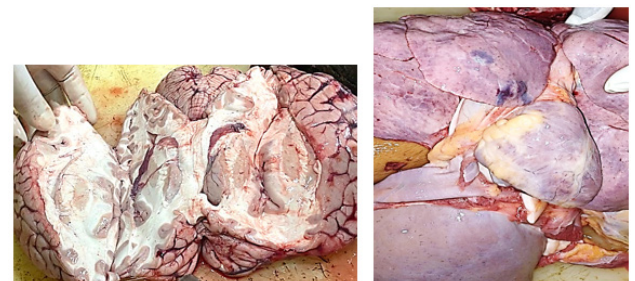

Fig 24. Pale and oedematous brain **Fig 25. All the internal organs - pale.**

- ❖ No tissues were preserved for further examination and no specimen preserved for chemical analysis.
- ❖ **Cause of death** was opined as '**MASSIVE HAEMORRHAGE CONSEQUENT TO MULTIPLE ANIMAL BITES [CANINES] OVER HEAD, NECK AND TRUNK**'.

Discussion

- (a) Telangana recorded 80281 cases of dog bites in 2022 and it has increased from 24000 in 2021.
- (b) The report on dog bite cases was tabled in the Lok Sabha by Bharati Pravin Pawar, Minister of state, Ministry of Health and Family welfare. The report stated that Telangana stood 8th in terms of dog bite cases reported in 2022.
- (c) India has witnessed a surge in the cases of rabies in the last decade.
- (d) According to a report by the World Health Organization, approximately 35 million stray dogs live in India while 18 to 20 thousand rabies cases occur every year that accounts for 36 per cent of the world's deaths from rabies. (<https://mediaindia.eu/society/stray-dogs-a-major-problem-in-india/>).
- (e) The World Health Organization (WHO) target of ending human rabies deaths globally by 2030 will not be achieved unless India succeeds as it accounts for a large percentage rabies cases in the world.^[5]
- (f) The number of stray dogs in India is unfortunately on the rise due to lack of proper sterilization drives in the country. Activities such as animal control policies (including spaying and neutering), lack of animal welfare project implementations by civic bodies only add to the stray dog bites and attacks.
- (g) Stray dog population is controlled by sterilisation of Stray dogs by implementing ABC-ARV Programme as per the Animal Birth Control (Dog) Rules-2001.^[6]
- (h) The tips of the ears of the sterilised stray dogs are cut in 'V' shape mark for identifying the stray dogs which have undergone sterilisation operation in ABC-ARV Programme.^[6]
- (i) Animal Birth Control Operation will reduce sexual aggression, maternal aggression and ARV programme will prevent the rabies disease in dogs. Territorial aggression, food aggression, fear aggression is natural to dogs which cannot

be controlled, hence public should behave appropriately with the stray dogs.^[6]

- (j) In the ABC-ARV Programme, all the stray dogs are vaccinated against Rabies soon after the Animal Birth Control Operation and they are revaccinated every year.^[6]
- (k) Animal Laws in India to protect stray dogs:^[8]
 - I. The Animal Birth Control (Dogs) Rules, 2001
 - II. Section 428 of the Indian Penal Code, 1860
 - III. Prevention of Cruelty to Animals (PCA) Act, 1960
 - IV. The Delhi High Court states that there are no laws that prohibit people from feeding stray animals. It is a crime to threaten, abuse or harass neighbours who feed animals. (Section 506)
 - V. Can file a complaint with the nearest local police station under Section 428, 429 IPC (Indian Penal Code) if the Resident Welfare Association is not cooperative.

Source of funding: SELF.

Ethical clearance: Taken from Institutional Ethics Committee, Osmania medical college.

Conflict of Interest: NIL.

References

1. Kleszcz A, Cholewińska P, Front G, Paoń J, Bodkowski R, Janczak M, Dorobisz T. Review on Selected Aggression Causes and the Role of Neurocognitive Science in the Diagnosis. *Animals (Basel)*. 2022 Jan 24;12(3):281. doi: 10.3390/ani12030281. PMID: 35158605; PMCID: PMC8833765.
2. Ananthanarayan and Paniker's Textbook of Microbiology 10th edition 2017
3. 10 signs of rabies in dogs and 3 prominent stages, by Jennica Johnson Msc Jan 18-2022
4. Rupprecht CE. Rhabdoviruses: Rabies Virus. In: Baron S, editor. *Medical Microbiology*. 4th edition. Galveston (TX): University of Texas Medical Branch at Galveston; 1996. Chapter 61. Available from: <https://www.ncbi.nlm.nih.gov/books/NBK8618/>
5. Zero by 30: the global strategic plan to end human deaths from dog-mediated rabies by 2030
6. ANIMAL BIRTH CONTROL (DOGS) RULES, 2001, Gazette of India.
7. The six levels of dog bites – The Dunbar Bite Scale.
8. The wild life (protection) amendment act, 2002.