
Splenic Epithelial Cyst: A Rare Entity on Autopsy

Ruchi Agarwal¹, Swaran Kaur², Parul³, Parveen Rana⁴, Kulwant Singh⁵, Monika Gathwal⁶

¹Professor, ²Professor and Head of Department, ³Senior Resident, ⁴Professor, ^{5,6}Professor, Department of Pathology, BPS GMC for Women, Khanpur Kalan, Sonapat.

How to cite this article: Ruchi Agarwal, Swaran Kaur, Parul et al. Splenic Epithelial Cyst: A Rare Entity on Autopsy. Indian Journal of Forensic Medicine and Toxicology / Volume 18 No. 3, July - September 2024.

Abstract

Introduction: Splenic cyst is a rare entity with very few cases reported in literature. The diagnosis is usually incidental on autopsy, associated with symptoms due to enlargement, rupture, infection, or hemorrhage. It can be of two types - parasitic or nonparasitic cyst.

Case Report: Postmortem viscera of 33 year old male were received in the department of Pathology for histopathological examination. Grossly, an enlarged spleen weighing 180 gm and measuring 9x8x6 cm was identified. On cut section, an eccentric unilocular cyst measuring 7x6 cm was identified. The cyst was filled with brownish mucoid material and thickness of cyst wall was 0.1-0.2 cm. Microscopically, the cyst wall was lined by cuboidal epithelium with fibrocalcified wall.

Conclusion: Primary splenic cyst is a rare diagnosis. Although the diagnosis of splenic cyst can be established by radiological means, histopathology is mandatory to determine whether the cyst is primary or secondary in origin.

Keywords: Autopsy, epithelial cyst, spleen.

Introduction

Cystic disease of the spleen is a relatively rare entity usually encountered incidentally at time of autopsy having an incidence of 0.07%.¹ It may account for 30% of all splenic lesions and can be congenital, neoplastic, vascular, inflammatory or posttraumatic in origin.² Splenic hydatid cyst is the most common cystic lesion in spleen with an incidence of 0.5-4%.³

The mean age of presentation of splenic cyst is approximately 17 years with a slight female

preponderance. Nearly 80% of these cases are solitary, unilocular cysts at the time of initial presentation. The diagnosis is usually incidental on autopsy and it is associated with symptoms due to enlargement, rupture, infection or hemorrhage.⁴

The splenic cysts can be classified as secondary (pseudocyst) or primary (true) cysts. Also, primary cysts are further classified as parasitic and nonparasitic. About 10% of all splenic cysts are nonparasitic primary splenic cysts which are usually

Corresponding Author: Parul, Senior Resident, Department of Pathology, Bhagat Phool Singh, G.M.C. For Women, Khanpur Kalan, Sonapat, Haryana.

E-mail: parul.smgs@gmail.com

Submission date: February 2, 2024

Revision date: February 12, 2024

Published date: July 17, 2024

This is an Open Access journal, and articles are distributed under a Creative Commons license- CC BY-NC 4.0 DEED. This license permits the use, distribution, and reproduction of the work in any medium, provided that proper citation is given to the original work and its source. It allows for attribution, non-commercial use, and the creation of derivative work.

congenital in origin. Pseudocyst lacks an epithelial layer in the cystic lumen and is primarily induced by abdominal trauma. A true splenic cyst is one having an epithelial lining which are further categorised as epidermoid, dermoid or mesothelial types based on the type of lining. The luminal lining of true cyst is epithelial which can be readily be misidentified for endothelium. This diagnostic dilemma can be resolved by use of immunohistochemical stains like keratin and factor VIII. True splenic cyst lining is positive for keratin and negative for factor VIII.^{5,6}

True cysts and false cysts are typically identical on various imaging modalities like ultrasonography (USG) or computed tomography (CT) scan. Although pseudocyst typically have thicker fibrous walls, calcifications and internal debris and CT scan may give a relatively clearer picture regarding intracystic fluid, internal septations or calcifications. Final diagnosis is made using histopathological evaluation of the cyst wall lining only.⁷

Here, we report a rare case of epithelial splenic cyst diagnosed incidentally at the time of autopsy

Case Report

Post mortem viscera of a 33 year old male was received in the department of Pathology for histopathological examination. No significant past history or investigations were available in the post mortem papers. Pieces of both lungs, liver, spleen and both kidneys were received. Grossly, an enlarged spleen was identified weighing 180 gms and measuring 9x8x6 cm. On cut section, an eccentric unilocular cyst measuring 7x6 cm was identified with cyst wall thickness of 0.1 cm. The cyst was filled with brownish mucoïd material. No abnormality was identified in other visceral organs on gross examination.

Microscopic examination initially revealed fibrocollagenous tissue only. Following which extensive sampling was done which revealed cyst focally lined by flattened epithelial lining with fibrocalcified wall. The epithelial cells were positive for cytokeratin on immunohistochemistry. Surrounding splenic tissue was unremarkable.

Representative sections from both lungs, liver and both kidneys do not show any significant pathological change.

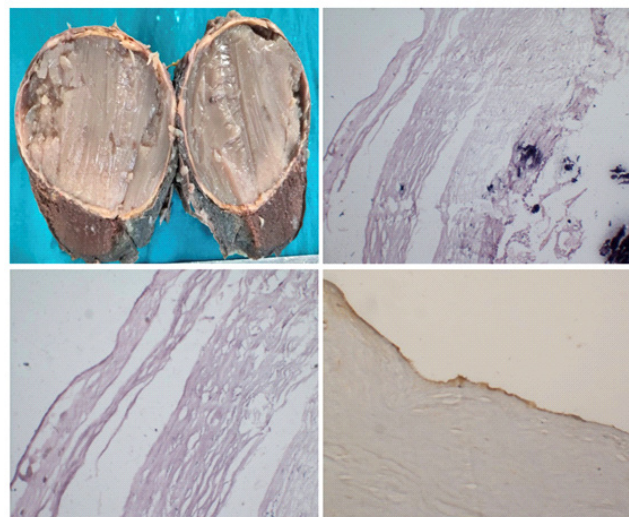


Figure 1 A: Gross specimen of splenic cyst containing mucinous material. B - Microphotograph from cyst wall showing fibrocalcified tissue (H&E 10X). C - Microphotograph from cyst wall showing flattened epithelial lining of cyst (H&E 20X). D - CK positive epithelial lining (IHC 20X).

Discussion

Splenic cystic lesions are extremely rare and infrequently observed in day to day surgical practice. They are predominantly seen in the second and third decade of life and are asymptomatic but can have symptoms related to the size of cysts like fullness of abdomen, local or referred pain or rarely thrombocytopenia. In a study conducted by Robbins et al over the span of 25 years out of 42,327 autopsies, only 32 cases were diagnosed with splenic cysts. In epithelial cysts, portions of the cyst wall can be desquamated and multiple sections may be required to identify the lining epithelium remnants. Failure to identify scant remnants of the epithelial lining can lead to erroneous classifications of these lesions as parasitic echinococcal disease, infarction, infection, pyogenic splenic abscess, cystic neoplasms like hemangioma/lymphangioma, tubercular abscesses, hydatid cyst or metastatic diseases of spleen. As each etiology has different clinical course and management, it is utmost importance to reach a final diagnosis.^{8,9,10}

Although the exact origin of true cysts remains unknown, it is believed that they arise from mesonephric tissue in the developing spleen

during the early stages of embryonic development. According to certain theories, they can also occur when peritoneal or mesothelial cells become trapped or infolded in the splenic parenchyma during fetal development.⁸

Kang et al reported a case of splenic cyst a 20-year-old female with history of abdominal pain. Following which laparotomy was done showing that the cyst was arising from the spleen. It was adhered to the left lateral side of the liver and left stomach wall. The pathologic report indicated a primary epidermoid splenic cyst with cyst walls lined by stratified squamous epithelial cells. The patient was discharged on the 10th postoperative day with an uneventful post-operative period.¹¹

In another study by Jeffrey A et al, a 32-year-old woman presented with a several months history of abdominal pain in her left upper abdomen. CT scan revealed a very large splenic cyst with compression of adjacent viscera and splenectomy was performed. The resected spleen measured 20 cm in diameter and weighed 3 kg. On cutting open, cyst cavity contained serous brown fluid. Microscopic examination revealed a single layer interior lining of cuboidal epithelium, consistent with the diagnosis of an epithelial cyst.¹²

Rana et al reported a case of 12-year-old female child with complains of dull pain, discomfort and feeling of fullness in left upper abdomen for 15 days. USG and CT scan showed an enlarged spleen with well-defined cystic mass measuring 10.2x8.4 cm in size. Splenectomy specimen revealed a large cystic lesion with a diameter of 10 cms on upper pole was discovered, with almost total replacement of splenic tissue at one side. Histopathological examination revealed stratified squamous epithelial lining of cyst and the diagnosis of splenic epidermoid cyst was confirmed. The postoperative clinical course of the patient was satisfactory and uneventful.¹³

In another study by Gupta et al, a case of simple epithelial cyst of the spleen was misdiagnosed clinicoradiologically as tubercular splenic abscess. A splenectomy specimen measuring 10x8x6 cm and weighing 266 gm was received. Cut section revealed a unilocular cyst measuring 7 cm in diameter. Histopathology revealed focal areas of denudation

showing intense inflammatory reaction with fibrosis in cyst wall. No granuloma or parasite were identified on serial sectioning of the cyst. Stain for acid fast bacilli and fungus were negative. Final diagnosis of simple epithelial cyst spleen with rupture was made.¹⁴

In the present study, there was no history or investigation available in the post-mortem papers. Histopathological examination was consistent with a diagnosis of epithelial splenic cyst. This manuscript describes our experience of diagnosing a splenic cyst which was encountered accidentally at the time of autopsy. The distinction of various types of splenic cysts is important for efficient patient management because tubercular cysts, parasitic cysts, pyogenic splenic abscess, hydatid cyst or neoplasms can be easily identified on histopathological examination and further management for each of these diagnoses is different from one another.

Conclusion

Primary splenic cyst is a rare diagnosis. Although a diagnosis of splenic cyst can be established by radiological means, yet histopathology is mandatory to determine the exact etiology of cyst. Final diagnosis of nature of cyst will help the clinician to decide the further course of treatment.

Source of funding: none

Conflict of interest: nil

Ethical clearance: NA

References

1. Yoshikane H, Suzuki T, Yoshioka N, Ogawa Y, Hayashi Y, Hamajima E, Yokoi T. Giant splenic cyst with high serum concentration of CA 19-9. Failure of treatment with percutaneous transcatheter drainage and injection of tetracycline. *Scand J Gastroenterol.* 1996;31(5):524-6
2. Bürrig KF. Epithelial (true) splenic cysts. Pathogenesis of the mesothelial and so-called epidermoid cyst of the spleen. *Am J Surg Pathol.* 1988;12(4):275-81.
3. Humphreys WG, Johnston GW. Splenic cysts: a review of 6 cases. *Br J Surg.* 1979;66(6):407-8.
4. Hansen MB, Moller AC. Splenic Cysts. *Surg Laparosc Endosc Percutan Tech.* 2004;14(6):316-22.

5. Shukla RM, Mukhopadhyay M, Mandal KC, Mukhopadhyay B. Giant congenital infected splenic cyst: An interesting case report and review of the literature. *Indian J Surg*. 2010;72(3):260-2.
6. Palmieri I, Natale E, Crafa F, Cavallaro A, Mingazzini PL. Epithelial splenic cysts. *Anticancer Res*. 2005;25(1B):515-21.
7. Rana APS, Kaur M, Singh P, Malhotra S, Kuka AS. Splenic Epidermoid Cyst - A Rare Entity. *Journal of Clinical and Diagnostic Research*. 2014;8(2):175-6.
8. Morgenstern L. Nonparasitic splenic cysts: pathogenesis, classification, and treatment. *J Am Coll Surg*. 2002;194(3):306-14.
9. Robbins FG, Yellin AE, Lingua RW, Crsig JR, Turrill FL, Mikkelsen WP. Splenic epidermoid cysts. *Ann Surg*. 1978;187(3):231-5.
10. Dillemans B, Mottrie A, Decoster M, Gruwez JA. Epidermoid cysts of the spleen. *Acta Chir Belg*. 1993;93(6):265-7.
11. Kang SI, Jeon SY. Primary non-parasitic splenic cyst: a case report. *Korean J Hepatobiliary Pancreat Surg*. 2013;17(3):139-41.
12. Tabas JA, Strehlow M, Isaacs E. A false negative pregnancy test in a patient with a hydatidiform molar pregnancy. *N Engl J Med*. 2003;349(22):2172-3.
13. Rana AP, Kaur M, Singh P, Malhotra S, Kuka AS. Splenic epidermoid cyst - a rare entity. *J Clin Diagn Res*. 2014;8(2):175-6.
14. Gupta P, Dhingra KK, Garg A, Khurana N. Simple epithelial cyst of spleen: rare entity. *ANZ J Surg*. 2009;79(4):310-1.