

An Autopsy of Unrecognized Aftofin Herbal Solution Poisoning: A Case Report

Bakhtiyar Rashid Qader

**Sulaimani Medicolegal Institute, 7 Qanat Street, Kurdistan Regional Government,
Sulaimani, Sulaymaniyah, Iraq**

How to cite this article: Bakhtiyar Rashid Qader. An Autopsy of Unrecognized Aftofin Herbal Solution Poisoning: A Case Report. Indian Journal of Forensic Medicine and Toxicology / Volume 19 No. 1, January - March 2025.

Abstract

Background: Aftofin is a pure natural herbal remedy which is commonly used herbal solution therapy in ruminant animals. Livestock herders widely use herbal medicines for treatment of farm animals. Thus, animal herders or their family members are prone to a potential health risk from herbal drugs due to improper handling, irresponsibility and haphazard usage with careless protection and storage of these remedies. Up to date poisonings due to Aftofin herbal solution has not been previously outlined. The aim is to discuss mismanaged and description of the case follow-up.

Case presentation: A case reported on a 2-year-old girl who mistakenly ingested unknown volume of the drug. Consequently, she initially developed nausea; vomiting; abdominal pain; and elevated body temperature. In physical examination abdomen was distended with no bowel sound. Nasogastric tube immediately inserted and treated with supportive measurements. Laboratory results showed the patient in septic condition.

Conclusions: She passed away on fourth-day post ingestion. The cause of death was assigned due to septic shock resulting from intestinal perforation as outcome effects of the herbal solution ingredients. Public education and awareness among people and health professionals are necessary to be widened to protect from this type of poisonings and dramatic outcomes.

Keywords: Aftofin, Herbal, Poisoning, Autopsy, Case report

Background

Aftofin is a pure natural herbal remedy made of Peppermint Myrtle. It is commonly used herbal solution in treatment of all kinds of rashes, erosions, and dermal/mucosal blisters in ruminants (Cattle, Sheep and Goat). This herbal solution contains

variety of chemicals to achieve its application aim of production including tannins, phenolic acids and flavonoids⁽¹⁾. Nowadays, herbal medicines are widely utilized globally although they have a potential risk for health states of their users. The harmful effects of these sorts of drugs are usually due to irresponsible, improper handling and haphazard storage and

Corresponding Author: Bakhtiyar Rashid Qader, Sulaimani Medicolegal Institute, 7 Qanat Street, Kurdistan Regional Government, Sulaimani, Sulaymaniyah, Iraq.

E-mail: bakhtyar88@gmail.com

Submission date: May 18, 2024

Revision date: August 26, 2024

Published date: December 3, 2024

This is an Open Access journal, and articles are distributed under a Creative Commons license- CC BY-NC 4.0 DEED. This license permits the use, distribution, and reproduction of the work in any medium, provided that proper citation is given to the original work and its source. It allows for attribution, non-commercial use, and the creation of derivative work.

protection⁽²⁾. Chemical ingredients of the Aftofin solution includes Anthocyanins Caffeic acid, Gallic acid, Catechin, Myricetin and Quercetin, they are powerful tannin antioxidants with anti-inflammatory activities⁽³⁾. The most significant active component of this herbal solution is Menthol, which has anti-inflammatory and pain relief effects. Furthermore, this active ingredient has a strong minty odour and taste. In one study, it was reported that Menthol is fatal in dose of 50-500mg/kg, however recovery was recorded after single dose of 8 to 9 g⁽⁴⁾. Unfortunately, information on Aftofin toxicity was not announced by manufacture maker. To the best of our knowledge, a fatal poisoning case involving Aftofin herbal use has not been described before in the literature review. Thus, the main purpose of this case report on incautious drinking herbal solution is to increase awareness among farmers, public and healthcare professionals in order to prevent mysterious risks due to the misuse of herbal products.

Case presentation

Two years old female baby accidentally swallowed few amount of Aftofin herbal solution in barn; where the herbal solution was used for washing and disinfection of domestic cows by family members. Then 3 hours later, one family member observed discharged fluids coming out from her mouth. Therefore, they brought the child to a local health provider in their countryside. On next day, the patient was vigorously vomiting and there was noticeable rise of her body temperature. For that reason, she was immediately referred to pediatric hospital. On admission, she was crying, tired, and distended abdomen with repeated projectile vomiting. Clinical examination (Seen in table 1) manifests a mild elevation of temperature (38°C), with generalized abdominal tenderness and no bowel sounds (no bowel motion for 2days). In addition, the signs of vitality were normal and She looked very unwell, drowsy, pale, and yellowish discoloration of sclera with poor hydration. Her chest was clear by auscultation. the senior pediatric doctor referred the patient to intensive care unit.

Table 1: Clinical examination on admission

Clinical examination	Signs and symptoms
Consciousness	Lethargy and drowsy
Eye	Slightly yellowish color of sclera
Skin	Signs of dehydration
Abdomen	Distended, tender, no bowel sound detected, no organomegaly or mass detected
Signs of Vitality	No significant change apart from raised temperature
Chest	Bilaterally clear

At ICU, they were immediately inserted nasogastric tube to prevent further vomiting and risk of aspiration. Moreover, the patient was treated with supportive measurements. Sadly, the patient passed away on 4th day early morning. The deceased was sent to a medicolegal institute as it was a case of suspecting herbal poisoning without a professional diagnosis. On autopsy, the external examination was marked cyanosis of lips and nail of both hands with color of sclera turned to yellow. What's more, a tense unpleasant odor from mouth and bloating of abdomen were noticed.

On internal examination, after exploration of chest and abdomen, a tense foul and minty smell was sensed suggesting sever infection and peritonitis. All abdominal cavity was full of pus and internal organs adhered to each other i.e. frozen abdomen. Additionally, stomach was empty with signs of congestion and erosion and light hemorrhage of the gastric mucosa at places [Figure 1A and 1B]. Routinely, all internal organs were removed and examined looking for details. In proximal part small intestine, one point of greenish color leakage was found. Then a water pressure test applied to find the exact point of discharge and finally a tiny longitudinal tear (perforation) was discovered as shown in figure 2A and 2B. No clinically significant pathology was seen in rest of organs and tissues. The deceased had a survival period of 4 days, and there was no urine at the time of autopsy. Hence; viscera and blood were preserved and sent for chemical analysis to the concerned regional forensic laboratory. However, the chemical analysis report came negative for toxins.

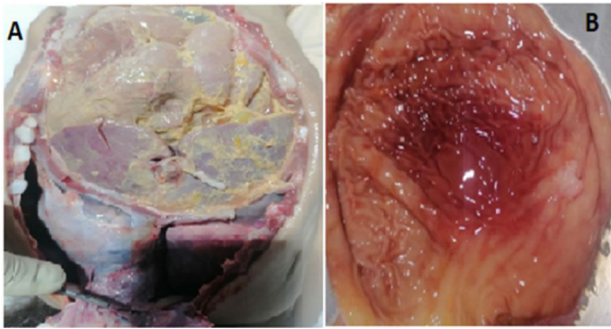


Figure 1: A- Chest and abdominal organs. B- Interior view of stomach

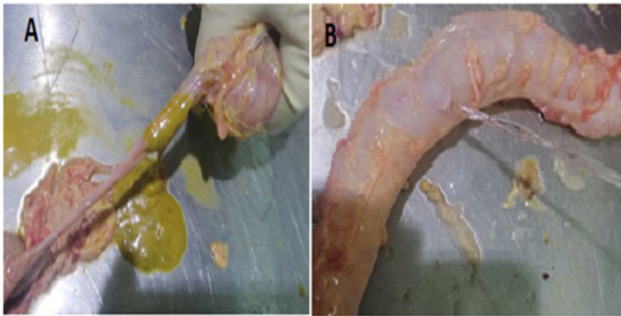


Figure 2: A- Leakage in intestine. B- Perforation site with water pressure test.

Discussion

Generally, herbal poisoning may frequently occur because of inadequate labeling and preservation, handling, overdose, and misidentification⁽⁵⁾. In the current report, the victim drank unknown amount of herbal solution that is used for domestic cow treatment and then her clinical features were quickly progressed in ways that she only survived 4 days after swallowing the mentioned herbal solution. Knowingly, undesirable outcomes of herbal medicines depend on the ingredients and the amount of used dose but a life threatening and rapid death consequence are clearly related to poisonous effects of the herbals⁽⁶⁾. In addition, Studies revealed that more than half of intensive care unit mortality is due to septic shock. Moreover, sepsis-related mortality has been estimated to raise by 7-10% in case each hour of septic treatment delay. Therefore, early detection of sepsis is quite imperative to reduce mortality and prevent unfavorable consequences⁽⁷⁾. For that reason, when the patient was admitted to hospital, they were immediately treated with supportive measurement and were prepared forward for laboratory investigations. The bowel injury found

during conducted autopsy was related to the patient's status that she didn't have bowel motion for 3 days along with that developed colic and abdominal bloating. These conditions can lead to erosion and event perforations of stomach and intestine due to continuous exposure to acid secretion of gastric origin. Moreover, it is known that bowel perforation can be secondary inflammation, infection, obstruction and usually the patient suffers abdominal pain and distention⁽⁸⁾. Moving to ingredients of Aftofin, Anthocyanins reviewed to have low toxicity on ingestion and causing abdominal pain, constipation, nausea and vomiting in case of high dose exposure⁽⁹⁾. Nevertheless, other components such as Quercetin, Catechins, Caffeic acid, Gallic acid and Myricetin are mentioned in literature review showing no adverse side effects or toxicity properties and even they are a normal element of a wide range of daily using fruits and vegetable^(3,10). Although, details in a brochure of Aftofin maker are mentioned with no any toxic components in the solution, Menthol was considered main active ingredient in the solution and on other side, it countered as toxic substance with lethal dose of 50-500mg/kg (1,10). Additionally, strong minty odor that has been sensed during autopsy is also supporting possibility of toxicity by Menthol. Furthermore, clinical feature of nausea and vomiting, abdominal pain, drowsiness, vertigo and constipation that were manifested by the patient, are observed in cases of Menthol overdose⁽⁴⁾. However, the results from toxicological screening were negative for toxins. But, a negative result from chemical analysis report does not rule out the toxicity. In addition, a postmortem toxicological screen result for a dead case of menthol inhalation poisoning was negative⁽¹¹⁾. If so, the diagnosis can primarily be determined by history taking and physical examination. In particular, the only clue for diagnosis of herbal toxicity may be based on a variety of clinical signs and symptoms⁽¹²⁾. Finally, the author has reached a conclusion that a possible explanation for child death is due to the complications of the active constitues of the ingested herbal solution particularly Menthol.

Conclusions

Herbal products should usually consider containing an active ingredient with highly toxic property. Therefore, their use for therapeutic

purposes, handling and preservation must be done with caution in order to avoid cases of poisoning which can sometimes have serious effect. In this case report, the 2 years old baby developed aggressive clinical course of severe gastrointestinal manifestation followed by death after the ingestion of ruminant herbal medicine. The autopsy findings revealed that delayed patient referral to emergency hospital played crucial role in early diagnosis and intervention, which are vital for a successful treatment. Thus, it is quite significant to create awareness and educate people and health professional about this kind of poisoning.

Acknowledgments: Deep thanks for my director for his valuable suggestions and support. I would also like to thank the staff members of autopsy department.

Conflict of interest: There are no conflicts of interest.

Ethical clearance: Since this is a case report no ethical clearance needed.

Consent for publication: taken from parents.

Funding: Not applicable

References

1. Vajgani M. Aftofin. Pars Imen Daru. Available from: <https://parsimendaru.com/product/aftofin/?lang=en> (accessed January 22, 2024).
2. Awodele O, Amagon KI, Usman SO, Obasi PC. Safety of herbal medicines use: case study of Ikorodu residents in Lagos, Nigeria. *Curr Drug Saf.* 2014;9(2):138-44.
3. Imran M, Nadeem M, Ali Shah SZ, Ullah MF, Bibi H, Ullah MF, et al. Myricetin: A comprehensive review on its biological potentials. *Food Sci Nutr.* 2021;9(10):5854-68.
4. Duke JA. Peppermint. In: Duke JA, editor. *Handbook of Medicinal Herbs*. 2nd ed. CRC Press; 2002. Available from: <https://doi.org/10.1201/9781420040463>
5. Vaerrier D. Herbal poisoning. Medscape. Available from: <https://emedicine.medscape.com/article/817427-overview?form=fpf> (accessed January 24, 2024).
6. Diaz JH. Poisoning by herbs and plants: rapid toxidromic classification and diagnosis. *Wilderness Environ Med.* 2016;27(1):136-55.
7. Langley RJ, Yende S, Reese CE, Angus DC, Kellum JA, Kahn J, et al. An integrated clinico-metabolomic model improves prediction of death in sepsis. *Sci Transl Med.* 2013;5(195):195ra95.
8. Jones MW, Kashyap S, Zabbo CP. Bowel perforation [Updated April 24, 2023]. In: StatPearls. Treasure Island (FL): StatPearls Publishing; 2024. Available from: <https://www.ncbi.nlm.nih.gov/books/NBK537224/>
9. Mattioli R, Francioso A, Mosca L, Silva P. Anthocyanins: a comprehensive review of their chemical properties and health effects on cardiovascular and neurodegenerative diseases. *Molecules.* 2020;25(17):3809.
10. Lira AB, Lima JD, Santos CD, Andrade CM, Silva FM, Nascimento SB. Isopropyl caffeate: a caffeic acid derivative – antioxidant potential and toxicity. *Oxid Med Cell Longev.* 2018;2018:6179427. doi: 10.1155/2018/6179427.
11. Kumar A, Baitha U, Aggarwal P, Jamshed N. A fatal case of menthol poisoning. *Int J Appl Basic Med Res.* 2016;6(2):137-9.
12. Brent J. Fomepizole for ethylene glycol and methanol poisoning. *N Engl J Med.* 2009;360(21):2216-23.