

# Outcome of Endoscopic Endonasal Repair of CSF Rhinorrhea using Fascia Lata Graft

Hani Musa Al-Akbi<sup>1</sup>, Ahmed Adhab Mayan<sup>2</sup>, Ammar Jabbar Najm Alkelabi<sup>3</sup>, Laith Ali Mahmood<sup>4</sup>

<sup>1</sup> Consultant Otolaryngologist, Gazi AL-Hariri Hospital for specialised surgeries, Medical City, Baghdad, Iraq, <sup>2</sup> Assistant Professor, Kufa University, College of Medicine, <sup>3</sup> ENT specialist, Gazi AL-Hariri Hospital for specialised surgeries, Medical City, Baghdad, Iraq, <sup>4</sup> ENT Specialist, Gazi AL-Hariri Hospital for specialised surgeries, Medical City, Baghdad, Iraq

## Abstract

Cerebrospinal fluid rhinorrhea occur when there is communication between skull base and the nasal cavity. Nowadays endoscopic endonasal repair of CSF rhinorrhea become the preferred surgical intervention.

**Setting:** ENT department at Ghazi AL Hariri Hospital for specialised surgeries, Medical City, Baghdad, Iraq.

**Aim:** To assess the effectiveness of fascia lata as sealing graft in the endoscopic endonasal repair of CSF rhinorrhea.

**Patients and Method:** Fifteen patients present to our department with possible clinical diagnosis of CSF rhinorrhea. The patients submitted to full history, examination including nasal endoscopy, radiological investigation (CT and MRI) of the nose and paranasal sinuses and skull base and CSF analysis. Operative technique was endoscopic endonasal repair using fascia lata graft .With monthly follow-up.

**Results:** Successful rate noted in 93% of the patients .No recurrence of meningitis attacks among those who reported meningitis on their presenting illness.

**Conclusion:** Endoscopic endonasal repair of CSF rhinorrhea has less operative and postoperative complication. Fascia lata graft offers a good choice for the repair.

**Key words:** CSF rhinorrhea, fascia lata graft and endoscopic endonasal repair.

## Abstract

A number of important etiologies may result in CSF rhinorrhea. The most common include accidental trauma, surgical trauma, congenital, tumors, and spontaneous (or idiopathic). Careful understanding of these etiologies is a prerequisite prior to devising a comprehensive diagnostic and management strategy for effective surgical repair of CSF rhinorrhea<sup>(1)</sup>. Approximately 80% of all cases of CSF rhinorrhea occur in the setting of accidental trauma, mostly in the form of closed-head injury. Conversely, CSF rhinorrhea is noted

in only 2% to 3% of cases of serious head trauma<sup>(2)</sup>. It is imperative to establish the diagnosis of CSF rhinorrhoea beyond doubt before considering surgical repair. If this is not done, patients may be subjected to unnecessary surgical intervention and it's attending morbidity<sup>(3)</sup>. Contraindications to the endoscopic treatment of CSF fistulas include the presence of an intracranial lesion; a fracture of the posterior wall of the frontal sinus; lateral extensions of the frontal and sphenoidal sinus, and CSF rhinorrhea from a temporal bone defect<sup>4</sup>. Aim of the study is to assess the effectiveness of fascia lata graft in the endoscopic endonasal repair of CSF rhinorrhea.

## Patients and Method

Across sectional study was conducted between March 2014 and November 2015 at ENT department,

---

**Corresponding author:**

**Laith Ali Mahmood**

E-mail: drlaith2006@yahoo.com.

Ghazi AL-Hariri for specialised surgeries Hospital, Medical City Complex, Baghdad, Iraq. Fifteen patients (eight males and seven females) were with a possible clinical diagnosis of CSF rhinorrhea. The duration of symptoms ranged from two months to twelve years. All patients had failed conservative treatment.

All patients underwent a thorough clinical history, endoscopic examination of nasal cavity, and the glucose concentration of the nasal discharge (CSF) was analyzed. All our patients underwent computed tomography (CT) and magnetic resonance imaging (MRI); CT scan was helpful in showing fracture site in post-traumatic CSF rhinorrhea while MRI was beneficial in detecting meningocele. Inclusion criteria was both the traumatic and non-traumatic CSF leak. Patients with skull base tumor were excluded from the study. Endoscopic examination where done using local decongestant and topical anesthesia using 0 degree rigid scope and the findings were difficult to localize the exact site of CSF leak, but the leak was noted coming from sphenoethmoidal recess or frontoethmoid area other patients with an obvious meningocele was noted specially in pediatric age group. Our surgical option was endoscopic endonasal repair of CSF rhinorrhea using tensor fascia lata as sealing graft. All surgeries done under general anesthesia with oral endotracheal intubation. Patients lie in slightly reverse trendelenberg position. In cases werethe defect in the cribriform area or from sphenoethmoidal area ,we lateralized the middle turbinate to get access to those areas ,sometimes we did complete ethmoidectomy to get access to the fovea ethmoidalis, In cases were a meningocele is present we follow it till reaching its neck and visualize the defect which coming from. The most critical step in the repair was to cauterize all the mucosa surrounding the defect and denuded the bone by using a bipolar suction diathermy to help get a good ground for the graft. A fatty tissue which obtained from the patient thigh plugged into the defect (underlay) ,after that an appropriately sized tensor fascia lata graft ( 30% larger than the defect due to later shrinkage of the graft ) is insinuated into the defect a few millimeters.then a gelfoam sponge was inserted to support the graft and a Merocil (Kennedy) pack was inserted and it was removed at third or fifth day; once the packs were removed; an endoscopic examination is done to remove any crustation and to get the first look after the surgery .The patients were instructed to minimize their daily activity like weight lifting, upstairs, sex, and avoid constipation by eating rich fiber diet . Patients were

advised for monthly visit for endoscopic examination and assessment.

## Results

Fifteen patients were with diagnosed of CSF rhinorrhea their age range from two years to fifty five years. Duration of symptoms range from two months to twelve years, eight patients were male and seven patients were female (figure 1); six patients experienced CSF leak from the left side while the other nine patients had the leak from the right side (figure 2).

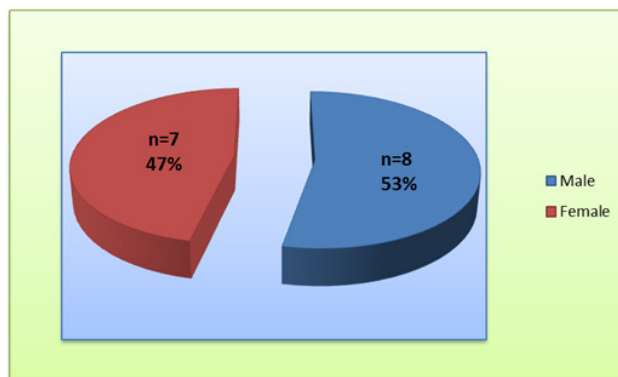


Figure (1) Gender ratio

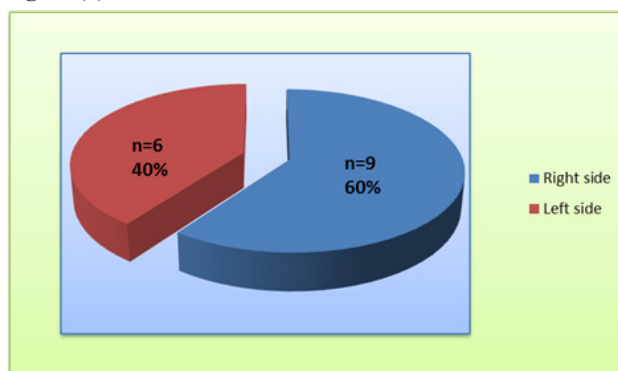


Figure (2) : EIGHT PATIENTS HAD HISTORY OF HEAD TRAUMA (OF THOSE, THREE PATIENTS HAD PREVIOUS NASAL SURGERY) WHILE THE REMAINING SEVEN PATIENTS HAD NON TRAUMATIC CSF RHINORRHEA (FIGURE3).

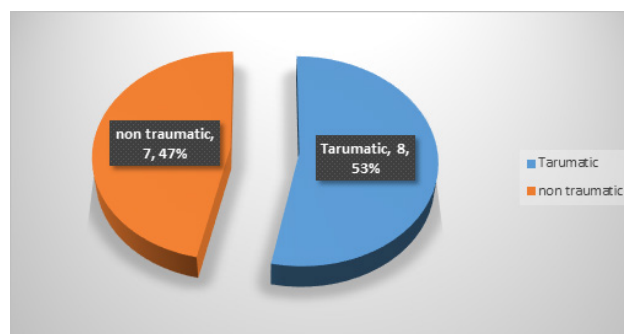


Figure (3)traumatic versus spontaneous CSF leak

Of those fifteen patients, five patients reported history of meningitis (ranging from one to several

attacks during their illness); the other patients had no such history, figure (4).

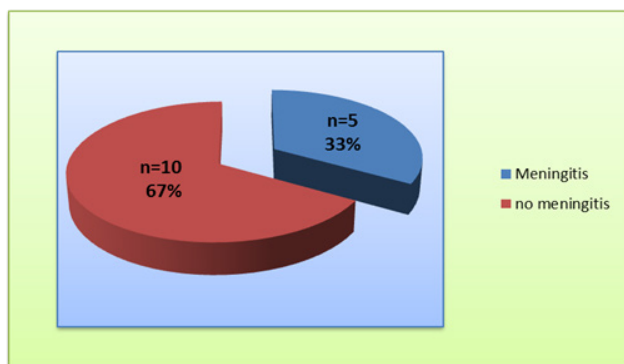


Figure (4) meningitis rate

Eight patients were founded have a meningocele during the surgery; five meningocele were originated from cribriform plate, two meningocele were originated from fovea ethmoidalis, while one patient had a sphenoidalmeningocele, figures (5),(6)

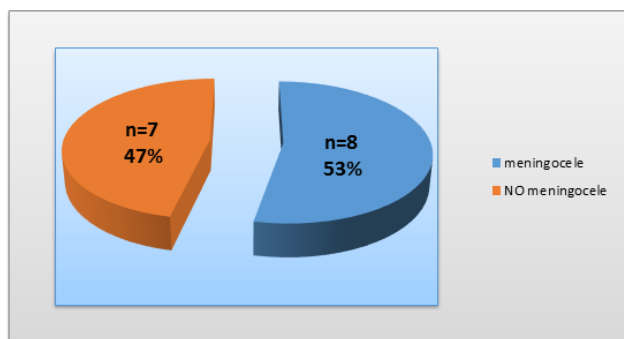


Figure (5)rate of meningoceles

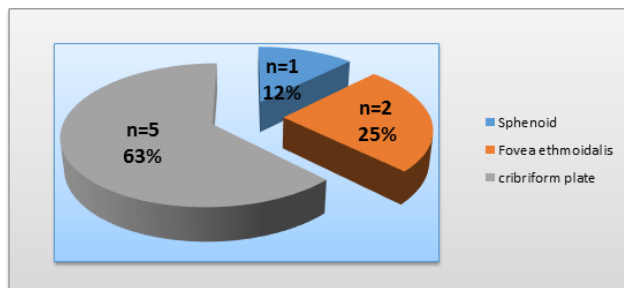


Figure (6) origin of meningoceles

Regarding CSF rhinorrhea without meningocele; the sites of the leaks were; three patients had leaks from cribriform plate; three patients had leaks from fovea ethmoidalis and one patient had leak from frontal sinus.

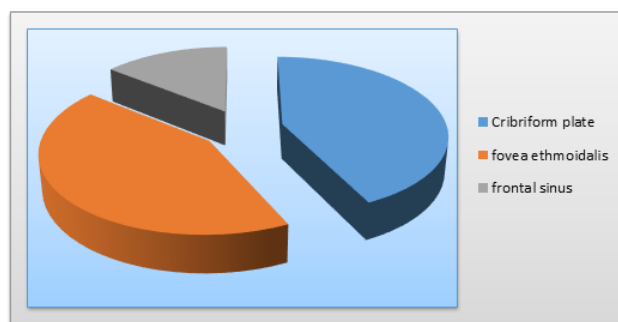


Figure (7) sites of CSF leak without meningocele

Only one patient presented with recurrence of CSF rhinorrhea one month after surgery. Other patients did not report any rate of CSF rhinorrhea all over the follow up period. Patients with previous attacks of meningitis, they were free from it after the surgery.

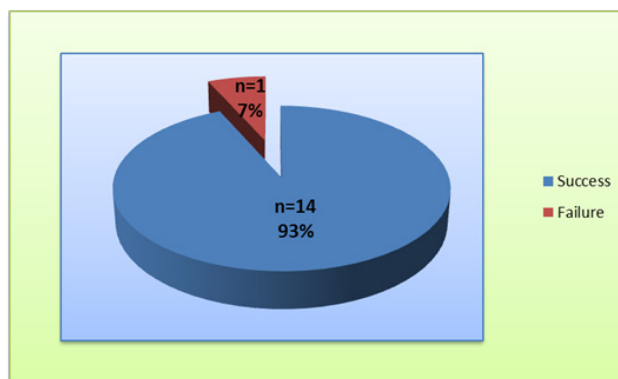


Figure (8)Success / failure ratio

### Discussion

In our country; CSF rhinorrhea had been treated surgically by neurosurgeons using open approach (craniotomy) for many years with its highly morbidities and mortalities. In the last few years a great move done in our otolaryngology department Ghazi AL Hariri hospital to treat such cases with CSF rhinorrhea by endonasal endoscopic approach. In our study male with CSF rhinorrhea more common than female. Yong-Gang Kong et al (2013), found seventeen male and five female among 22 cases with CSF rhinorrhea. <sup>5</sup> Thibaut Van Zele et al (2013), found five female and one male among six patients. <sup>6</sup> Majority of our cases (53.3%) were traumatic, which is similar to most other study. S. Schmerber et al (2006), found six patients had spontaneous leak and sixteen patients had traumatic CSF leak. <sup>7</sup> Muhammad Umar Farooq and Murtaza Ahsan Ansari (2011), also found the same rate. <sup>8</sup> In our study all patients submitted MRI, Bernardo Cunha Araujo Filho et al (2005), Order MRI only for suspected cases of meningoencephaloceles. <sup>9</sup>, José Alberto Landeiro et al (2004), ordered MRI for all patients. <sup>10</sup> We had five cases of meningitis, Bernardo

Cunha Araujo Filho et al (2005), report one case among 44 cases.<sup>9</sup> Yong-Gang Kong et al (2013) found four cases among twenty two patients<sup>(5)</sup>, Mazhar Husain et al (2006), found three patients had meningitis among nine patients.<sup>11</sup> Antibiotics cover used for all our patients, Friedman JA et al (2001), adopted antibiotics for all patients.<sup>12</sup> We have eight cases with meningocele among our patients. Yong-Gang Kong et al (2013), had two cases among 22 patients.<sup>5</sup> In our study, majority of our cases had leak from lateral lamella of cribriform plate 53.33%. Bernardo Cunha Araujo Filho et al (2005), found the same.<sup>(9)</sup> Silva et al (2006), found sphenoid bone involved more commonly than ethmoid bone.<sup>(13)</sup> The success rate was of CSF closure in our study was 93.33%. Kirtane et al (2005), had success rate of 96.63%.<sup>(14)</sup> Bernardo Cunha Araujo Filho et al (2005), 80% success rate.<sup>(9)</sup> Schick et al (2001), report success rate of 80%.<sup>(15)</sup>

### Conclusion

Nowadays endoscopic endonasal repair of CSF rhinorrhea become the preferred option for the repair of CSF rhinorrhea with fascia lata graft offer a good choice for the repair in both traumatic and spontaneous CSF leaks with high successful rate.

**Financial Disclosure:** There is no financial disclosure.

**Conflict of Interest:** None to declare.

**Ethical Clearance:** All experimental protocols were approved under the Gazi AL-Hariri Hospital for specialised surgeries, Medical City, Baghdad, Iraq and all experiments were carried out in accordance with approved guidelines.

### References

- Ommaya AK, Di Chiro G, Baldwin M, et al.: Non-traumatic cerebrospinal fluid rhinorrhoea. *J Neurol Neurosurg Psychiatry*. 31:214-225 1968.
- Lloyd KM, DelGaudio JM, Hudgins PA. Imaging of skull base cerebrospinal fluid leaks in adults. *Radiology* 2008; 248:725-736.
- Bateman N, Jones NS. Rhinorrhoea feigning cerebrospinal fluid leak: nine illustrative cases. *Journal of Laryngology and Otology*. 2000; 114: 462-4.
- Harvey RJ, Smith JE, Wise SK, et al. Intracranial complications before and after endoscopic skull base reconstruction. *Am J Rhinol* 2008; 22:516-521.
- Yong-Gang Kong • Yu-Qin Deng • Yan Wang , Transnasal Endoscopic Repair of Cerebrospinal Fluid Rhinorrhea: An Analysis of 22 Cases, *Indian J Otolaryngol Head Neck Surg* .2013; 65(2):S409-S414.
- Thibaut Van Zele, M.D., Ph.D., Adriano Kitice, M.D., Eduardo Vellutini, M.D., Leonardo Balsalobre, M.D., and Aldo Stamm, M.D., Ph.D., Primary spontaneous cerebrospinal fluid leaks located at the clivus, Address correspondence and reprint requests to Thibaut Van Zele, M.D., Ph.D., Department of Otorhinolaryngology, Ghent University Hospital, Ghent, Belgium, De Pintelaan 185, 9000 Ghent, Belgium, OceanSide Publications, Inc., U.S.A. 2013.
- S Schmerber MD, Ch. Righini MD, JP Lavielle, MD. Endonasal Endoscopic Closure of Cerebrospinal Fluid Rhinorrhea, Departments of Ear, Nose, and Throat Surgery and 2Neurosurgery, Grenoble Hospital, Grenoble, France. Copyright C 2001 by Thieme Medical Publishers, Inc., 333 Seventh Avenue, New York, NY 10001, USA.
- Muhammad Umar Farooq and Murtaza Ahsan Ansari, Cerebrospinal Fluid Rhinorrhea: Etiology, Site of Leakage and Endoscopic Management, *Journal of the College of Physicians and Surgeons Pakistan* 2011; 21(8): 460-463
- Bernardo C, Ossamu B, Francini G. Endoscopic repair of CSF rhinorrhea: experience of 44 cases, *brazilian journal of otorhinolaryngology*. 2005; 71 (4)1.
- José A, Marlo S, Bruno CR. surgical management of csf rhinorrhea under endoscopic control , *Arq Neuropsiquiatr* 2004;62(3-B):827-831.
- Mazhar H, Deepak J. Neuroendoscopic Transnasal Repair of Cerebrospinal Fluid Rhinorrhea, Department of Neurosurgery, King George's Medical College, Lucknow 226003, India, Copyright 2003 by Thieme Medical Publishers, Inc., 333 Seventh Avenue, New York, NY 10001, USA.2003.
- Friedman JA, Ebersold MJ, Quast LM. Post-traumatic cerebrospinal fluid leakage. *World J Surg* 2001; 25: 1062-6.

13. Silva LR, Santos RP, Zymberg ST. Endoscopic endonasal approach for cerebrospinal fistulae. *Minim Invasive Neurosurg* 2006; 49:88-92.
14. Kirtane MV, Gautham K, Upadhyaya SR. Endoscopic CSF rhinorrhea closure: our experience in 267 cases. *Otolaryngol Head Neck Surg* 2005; 132:208-12.
15. Schick B, Ibing R, Brors D, Draf W. Long-term study of endonasal duraplasty and review of the literature. *Ann Otol Rhinol Laryngol* 2001; 110: 142-7.