

## Tuberculosis of Ankle Joint: Case Series

Sonali Parida<sup>1</sup>, Priyadarshini Behera<sup>2</sup>, Chaitanya Kiran Gara<sup>3</sup>, Sangita Jena<sup>4</sup>

<sup>1,3,4</sup>Assistant Professor, <sup>2</sup>Associate Professor, Department of Pulmonary Medicine, IMS and SUM Hospital, Siksha 'O' Anusandhan, Deemed to be University, K8, Kalinga Nagar, Bhubaneswar, Odisha, India

**How to cite this article:** Sonali Parida, Priyadarshini Behera, Chaitanya Kiran Gara et. al. Tuberculosis of Ankle Joint: Case Series. Indian Journal of Public Health Research and Development/Volume 15 No. 1, January-March 2024.

### Abstract

Despite the widespread awareness campaigns going on worldwide for elimination of tuberculosis, knowledge on unusual forms of tuberculosis still remains low. We need to realize that tuberculosis can present in any form and thus, a greater degree of suspicion is important always especially in countries with high tuberculosis prevalence. Although skeletal tuberculosis is being increasingly diagnosed and treated, still tuberculosis of the ankle joint is uncommon and often misdiagnosed as septic arthritis and thus leads to unnecessary delay in treatment. Sometimes another focus of tuberculosis elsewhere in the body may be not found nor do the patients have any presumptive tuberculosis symptom. It is equally important to know that surgery alone might not help these patients. a combination of surgery and appropriate anti tubercular therapy is the right approach. So, a multidisciplinary role and co operation of the surgeon as well as the physician is essential especially in cases of skeletal tuberculosis. Hence, it is imperative to know about tuberculosis irrespective of the system or anatomical structure involved.

**Key words:** tuberculosis, ankle joint

### Introduction

Tuberculosis continues to haunt mankind since its inception. Tuberculosis affected 9.9 million people worldwide in 2020 and causing death in 1.3 million people <sup>(1)</sup> 23-30 % of all TB cases are extra pulmonary TB and 1-3% of those cases are skeletal tuberculosis<sup>(2)</sup> Foot and ankle joint tuberculosis constitutes about 1% of all cases of tuberculosis<sup>(2,3,4)</sup>. Ankle joint tuberculosis is very uncommon. The most commonly affected bone in ankle joint tuberculosis is the Calcaneum<sup>(2)</sup>. Unusual site, similarity to other ankle joint disorders, lack of awareness regarding skeletal tuberculosis lead to delay in appropriate diagnostic evaluation and treatment. We present a series of

5 cases of ankle joint tuberculosis presenting to the department of Pulmonary Medicine with varied manifestations.

### Material and Methods

All the cases mentioned here were OPD or Indoor patients of the department of Orthopedics and Pulmonary medicine. Other causes of ankle joint arthritis were excluded by appropriate imaging studies, histopathological tests and routine blood tests.

#### Case 1:

A 28 year old male without any co morbidities presented to the hospital with left severe foot pain

---

**Corresponding Author:** Sangita Jena, MD, Department of Pulmonary Medicine, IMS and SUM Hospital, Siksha 'O' Anusandhan, Deemed to be University, K8, Kalinga Nagar, Bhubaneswar-751003, Odisha, India.

**Mobile:** 7682959171

**E-mail:** sangini.dr@gmail.com

---

and restriction in movement which was gradually progressive since last 6 months. The pain increased in intensity since last 1 month after a minor blunt trauma to the left foot. There was absence of presumptive TB symptoms. He was a farmer and was addicted to tobacco and was of low socio economic status. He did not have any past history of Tuberculosis or contact history with any TB patient. He also did not have any hereditary blood disorders. Physical examination revealed BP - 110/60 mm Hg, respiratory rate of 18/min, pulse rate of 90/min and SpO<sub>2</sub>- 99 % at room air and a marked reduction in movement and swelling and tenderness of the left ankle joint. Dorsalis pedis artery pulsation was normal. There was no abnormality in other joints and rest of the systems were normal on examination. Routine blood tests were all normal.

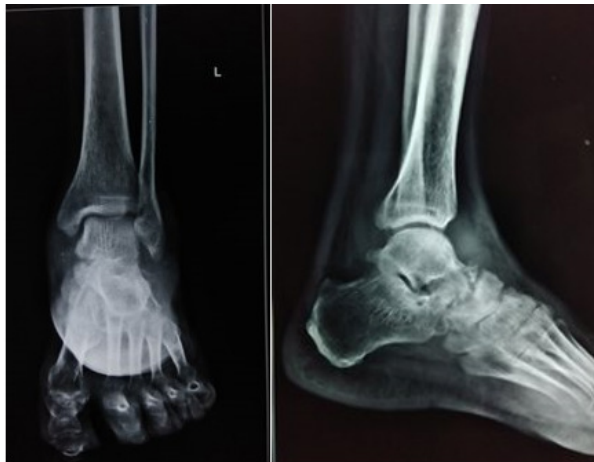

Fig 1

Fig 2

X Ray of left ankle joint showed talonavicular and calcaneocuboid joint arthritis features and reduction in joint space and pathological fracture of anterior tubercle of talus and a prominent poster lateral tubercle of talus. Orthopedics opinion was taken and the patient underwent debridement and biopsy which was on histopathology was suggestive of TB. However, the biopsy sample on AFB staining and CBNAAT did not detect *Mycobacterium tuberculosis*. He was administered weight appropriate anti tubercular treatment and showed good weight gain and clinicoradiological improvement during follow up visits.

#### Case 2:

A 46 year old male without any comorbidity presented to the hospital with moderate pain and

swelling of right foot for 3 years. He also complained a low grade intermittent fever for last 2 months and an unintentional weight loss of 7 kg in 2 months as well as low appetite. He denied any trauma history. He was a bank clerk and was of low socioeconomic status. He did not have any addictions or habituations and never had any past or contact history of tuberculosis. On examination BP was 130/80 mm Hg, pulse rate was 80/min, respiratory rate- 20/min, SpO<sub>2</sub> was 98 % with room air and there was swelling, tenderness and restriction in range of motion of the right ankle joint with preserved normal pulsation of the Dorsalis pedis artery and without any distal neurovascular deficit. Other systems were normal on examination. Routine blood tests were normal except for a hypochromic, microcytic anemia and a high ESR.

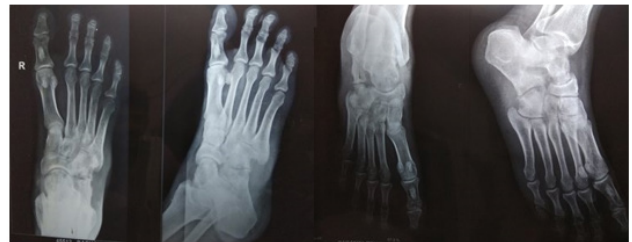

Fig 3

Fig 4

X ray of right ankle joint showed tibiotalar joint space reduction with destruction of talus. As per Orthopedics opinion the patient underwent calcaneocuboid joint capsulotomy and synovial tissue was sent for histopathology which was favorable for tuberculosis. AFB staining was negative but *Mycobacterium tuberculosis* sensitive to rifampicin was detected in CBNAAT in the tissue. Antitubercular therapy was initiated and he showed significant improvement during the two month follow up with subsidence of fever, decrease in pain, weight gain, improvement in appetite.

#### Case 3:

A 25 year old male presented to the hospital with progressive pain in the left foot interfering with his routine activities and loss of appetite for 1 year. There was no fever or weight loss. He did not have any pre existing co morbid illness. He never had any contact with any TB patient nor did he have TB in the past. There was no trauma history or any other presumptive TB symptoms. General examination revealed BP- 120/74 mm Hg, pulse rate of 78/min,

respiratory rate of 18/min, SpO<sub>2</sub>- 99 % with room air. On examination there was left ankle joint swelling and tenderness, decrease range of motion but no distal neurovascular deficit and preserved Dorsalis pedis artery pulsation. All other joints and systems were normal on examination. Routine tests were normal except for a hypo chromic, microcytic anemia.

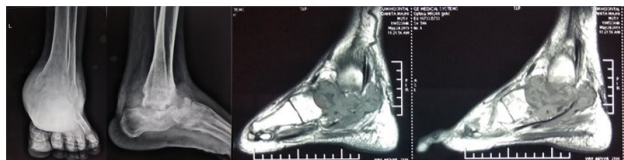

Fig 5

Fig 6

Fig 7

X ray of left ankle showed erosion of talarbody, tibiotalar joint space erosion and erosion of articular margins. MRI left ankle was suggestive of septic arthritis. After Orthopedics consultation he underwent left ankle arthrotomy, joint clearance and biopsy was taken from the site which on histopathological examination indicated Tuberculosis. AFB stain

and CBNAAT tests were however negative for mycobacteria. He was started on Antitubercular treatment and underwent physiotherapy after 1 month of surgery. He responded well with resolution of symptoms on subsequent follow up visits.

#### Case 4:

A 26 year old male without any previous illness including TB presented to the hospital with progressive swelling and pain of left foot for 6 months. He also had loss of appetite and a weight loss of 8 kgs over 3 months. On examination pulse rate was 100/min, SpO<sub>2</sub> was 98 % with room air, respiratory rate - 20/min and BP- 126/70 mm Hg. There was tenderness, swelling of left ankle joint with decreased range of motion but without any distal neurovascular deficit or reduction in Dorsalis pedis arterial pulsation. Rest of the joints and other systems were normal on examination. Routine tests were all normal except an elevated ESR.

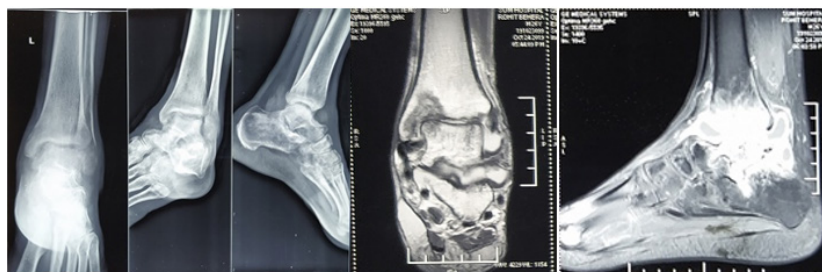


Fig 8

Fig 9

Fig 10

X ray of left foot showed reduction of tibiotalar joint space, erosion of talus and Calcaneum. MRI of left ankle joint showed features of septic arthritis. A left ankle arthrotomy was done and synovial tissue biopsy was taken which on histopathology revealed granulomatous inflammation. AFB staining was negative but tissue CBNAAT detected Mycobacterium tuberculosis. He had good clinico radiological improvement with ATT.

the ankle joint on the right and decreased range of motion and no signs of neurovascular deficit. All routine blood tests were normal. X ray revealed mild osteopenia involving talus, calcaneus, navicular as well as cuneiform bones. MRI ankle joint showed features of acute arthritis.

#### Case 5:

A 50 year old female without any comorbidity presented with right ankle pain and swelling and a low grade intermittent fever for 1 year. There was no weight loss or loss of appetite. On examination pulse rate was 78/min, SpO<sub>2</sub> was 99% with room air, respiratory rate - 18/min and BP- 100/70 mm Hg. There was swelling, tenderness and crepitus in

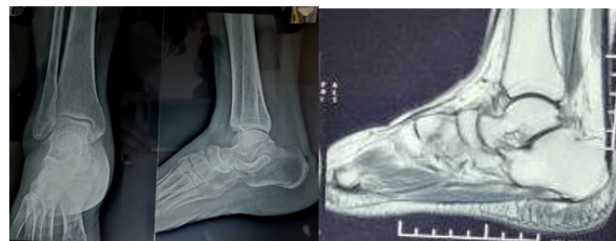

Fig 11

Fig 12

She underwent right talonavicular arthrodesis with biopsy of the hypertrophied synovium which was suggestive of Tuberculosis. AFB staining

and CBNAAT were negative for Mycobacterium shown good clinical improvement in subsequent tuberculosis. She was started on ATT and has follow ups.

### Findings

**Table 1: Routine blood investigations:**

| Serial no | Hb   | TLC  | sodium | pot | urea | creat | LFT | FBS | PPBS | ESR |
|-----------|------|------|--------|-----|------|-------|-----|-----|------|-----|
| 1         | 12.1 | 5600 | 131    | 3.5 | 60   | 1.0   | N   | 100 | 123  | 20  |
| 2         | 9.0  | 6700 | 135    | 3.2 | 40   | 0.8   | N   | 92  | 110  | 120 |
| 3         | 8.2  | 8800 | 130    | 3.7 | 30   | 0.5   | N   | 90  | 100  | 30  |
| 4         | 13   | 7300 | 133    | 3.6 | 40   | 0.7   | N   | 116 | 120  | 130 |
| 5         | 12   | 6700 | 135    | 3.2 | 43   | 0.3   | N   | 105 | 119  | 92  |

**Table 2: Radiological profile:**

| Serial no | X ray - ankle joint   | MRI- ankle joint   |
|-----------|---|--|
| 1         | talonavicular and calcaneocuboid joint arthritis features and reduction in joint space and pathological fracture of anterior tubercle of talus and a prominent posterolateral tubercle of talus | Not done   |
| 2         | Tibiotalar joint space reduction with destruction of talus  | Not done   |
| 3         | Erosion of talar body, tibiotalar joint space erosion and erosion of articular margins  | Gross destruction of talus with destructive changes in the distal tibial articular margin, articular margin of subtalar joint replaced by thick rim enhancing intercommunicating pockets of fluid collection and subarticular marrow STIR hyper intense signal changes showing post contrast enhancement |
| 4         | Reduction of tibiotalar joint space, erosion of talus and Calcaneum   | Irregular synovial thickening, joint effusion with intense peripheral rim of synovial enhancement, sub chondral erosion and marrow edema involving tibiotalar and talocalcaneal joint  |
| 5         | Mild osteopenia involving talus, calcareous, navicular and cuneiform bones  | Diffuse synovial thickening of tibiotalar, talocalcaneal and mid foot joints with post contrast enhancement of talus, calcareous, tibia, navicular, and cuneiform bones<br><br>No joint effusion   |

**Table 3: Mode of diagnosis of tuberculosis:**

| Serial no. | Surgery done  | Histopathology   | Microbiological confirmation  |
|------------|---|--|---|
| 1          | debridement and biopsy  | Numerous lymphocytes, epitheloid cells, necrotizing granulomas                           | AFB staining and CBNAAT negative  |
| 2          | calcaneocuboid joint capsulotomy and synovial tissue biopsy         | Caseating necrosis alongwith epitheloid cells and numerous multinucleated giant cells    | -AFB staining negative<br>-CBNAAT - <i>Mycobacterium tuberculosis</i> detected  |
| 3          | arthrotomy, joint clearance and biopsy                              | Numerous epitheloid cell granulomas with necrosis  | AFB staining and CBNAAT negative  |
| 4          | left ankle arthrotomy and synovial tissue biopsy                    | Laghan's giant cells with necrosis, lymphocytic infiltration                             | -AFB staining negative<br>-CBNAAT detected<br><i>Mycobacterium tuberculosis</i> |
| 5          | talonavicular arthrodesis with biopsy of the hypertrophied synovium | Predominant lymphocytes with epitheloid cells forming granulomas, some areas of necrosis | AFB staining and CBNAAT negative  |

### Discussion and Conclusion

Skeletal tuberculosis constitutes 11.3% of cases of Tuberculosis majority of which involve the spine followed by hip and knee joints<sup>(2)</sup>. Ankle joint involvement is quite uncommon.

#### Pathogenesis:

Hematogeneous dissemination of the tubercle bacilli leading to their growth in the joints is the primary mechanism involved. The joints which encounter trauma or inflammation are more prone to such infection in view of increased vascularity. Calcaneum is the most commonly affected bone in ankle joint tuberculosis owing to its high vascularity and continuous wear and tear<sup>(5)</sup>. Talus, first metatarsal and navicular are also affected commonly. If the synovium is infected first there is pannus formation leading to involvement of articular cartilage and subsequent spread to subchondral region whereas if only bone is infected first it leads to direct involvement of subchondral region by granulation tissue. Subchondral region involvement may lead to detachment of articular cartilage and collapse and degeneration of the joint<sup>(6)</sup>.

#### Stages of articular tuberculosis

First stage -only synovial lining involved without bony erosion

Second stage -bony erosion without reduction of joint space

Third stage- involvement of synovium and erosion of bone as well as joint space reduction

Fourth stage- bony architectural destruction, involvement of contiguous joints or phylogenic arthritis<sup>(6,7)</sup>.

#### Clinical features:

Pain, swelling, redness and reduced range of motion of the joint. Enlargement of inguinal lymph nodes. If untreated discharging sinuses and ankylosis can be seen. Other symptoms of tuberculosis like fever, loss of weight and appetite can also be seen. There can be many differentials of tuberculosis ankle joint like sarcoidosis, septic arthritis, amyloidosis, Charcot's arthropathy, malignancy. Favorable outcomes are seen with early diagnosis and appropriate treatment.

#### Investigations:

X rays usually show articular erosions which can take 2-5 months to be visible on radiographs. The investigation of choice is MRI which can show joint edema, synovial thickening, effusion, subchondral lytic lesions, osteopenia<sup>(7)</sup>. Usually diagnosis is confirmed by histopathological examination of bone or soft tissue from the infected site revealing caseation

necrosis, Langhan's giant cells, granulomas. Tissue can also be sent for CBNAAT test for quick detection of *Mycobacterium tuberculosis*.

#### Management:

Anti tubercular treatment should be continued for 6 to 18 months depending on the clinic radiological response<sup>(5)</sup>. Since it is paucibacillary prolonged therapy should be considered always in view of dormant bacilli. Surgical procedures may be required like arthrodesis, debridement, curettage, surgical removal of sequestered/destroyed bones<sup>(8)</sup>.

#### Conclusion

In high TB prevalence areas any chronic ankle joint inflammation should be thoroughly worked up for evidence of TB. Early diagnosis and prompt initiation of treatment plays a great role in achieving clinicoradiological resolution.

**Declaration of conflicting interests:** The authors declared no potential conflicts of interests

**Informed consent:** Written informed consent was obtained from the patient.

**Funding Resources:** Self

**Ethical clearance:** Approved by Institutional Ethical Committee.

#### References

1. Tuberculosis data: provisional TB notifications by month or quarter [website]. Geneva: World Health Organization; 2021 (<https://www.who.int/teams/global-tuberculosis-programme/data>)
2. Jockheck M, Meeder PJ, Weller S. Die tuberkulöse Destruktion des Talus-Eine seltene Form der extrapulmonalen Skelett-TBC-Eine Fallbeschreibung. *Zeitschrift für Orthopädie und ihre Grenzgebiete*. 1992 Jan; 130(02):163-5.
3. Dhillon MS, Aggarwal S, Prabhakar S, Bachhal V. Tuberculosis of the foot: An osteolytic variety. *Indian journal of orthopaedics*. 2012 Apr;46:206-11.
4. Anderson JR, Ritchie AW, Scobie WG. Tuberculous osteitis of the talus. *Tubercle*. 1979 Jun 1;60(2):115-8.
5. Kumar P, Dhillon MS, Rajnish RK, Jindal K. Tubercular involvement of the lateral malleolus and adjacent calcaneus: presentation of a rare case and review of the literature. *BMJ Case Reports CP*. 2019 Dec 1;12(12):e231533.
6. Korim M, Patel R, Allen P, Mangwani J. Foot and ankle tuberculosis: case series and literature review. *The Foot*. 2014 Dec 1;24(4):176-9.
7. Chen SH, Lee CH, Wong T, Feng HS. Long-term retrospective analysis of surgical treatment for irretrievable tuberculosis of the ankle. *Foot & Ankle International*. 2013 Mar;34(3):372-9.
8. Dhillon MS, Nagi ON. Tuberculosis of the foot and ankle. *Clinical Orthopaedics and Related Research (1976-2007)*. 2002 May 1;398:107-13.